

# Chest Radiography

## Lecture 16

### Pulmonary Nodule

Donald L. Renfrew, MD, FACR

[www.foxvalleyradiology.com](http://www.foxvalleyradiology.com)

# PULMONARY NODULE

**INDICATIONS:** Almost always an asymptomatic incidental finding.

**FINDINGS:** Well defined pulmonary density measuring less than 30 mm. Pulmonary masses (lesions > 30 mm) are generally handled as “focal lung density”. Please see separate presentation.

**IMPRESSION:** Pulmonary nodule. Comparison with prior studies to determine chronicity. Further work-up, typically starting with CT then (depending on results) proceeding to PET.

**COMMENT:** Cases in this category often require further work-up, frequently with additional imaging. However, at the time of the initial CR, the radiologist will not have these additional studies. The radiologist still needs to recognize the finding and that something more needs to be done.

# UpToDate Points

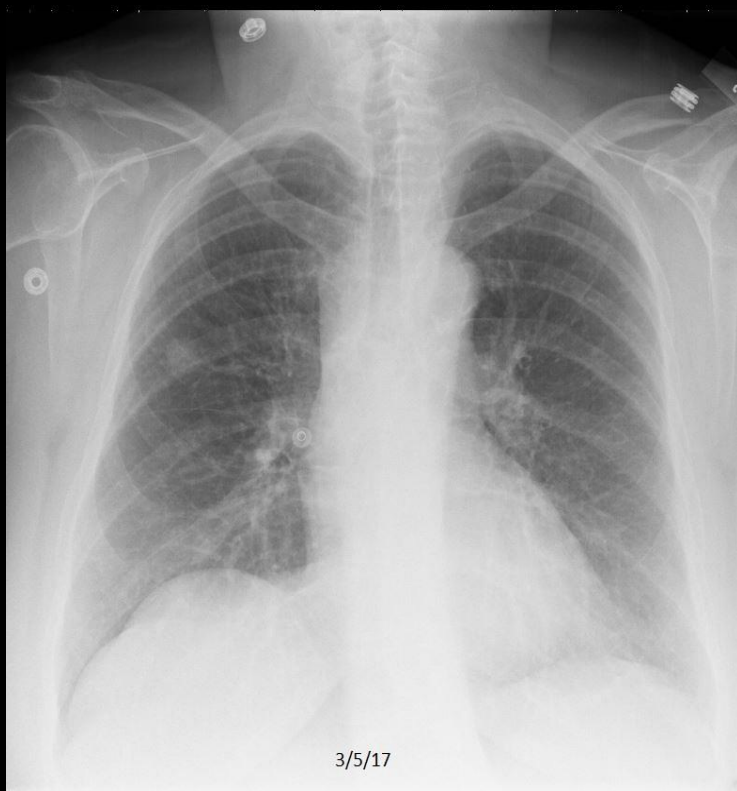
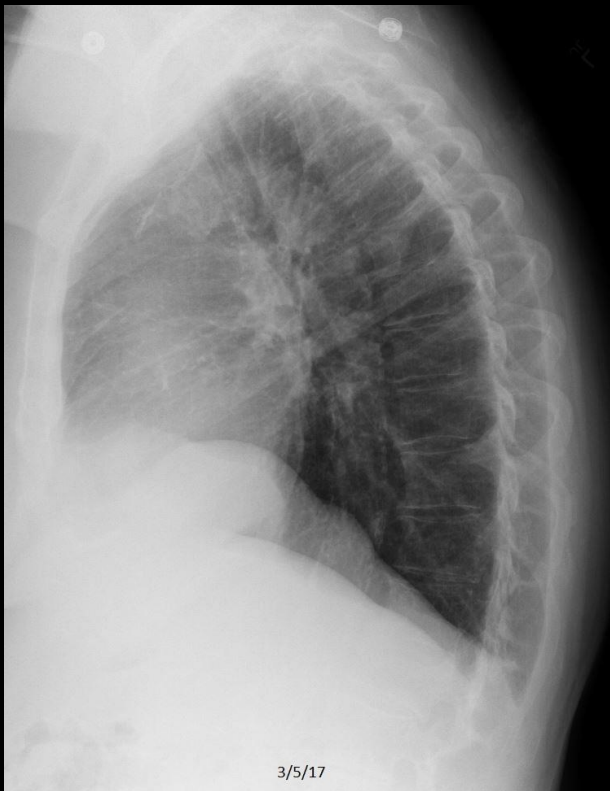"A pulmonary nodule is defined on imaging as small (<30 mm), well defined lesion completely surrounded by pulmonary parenchyma."

"The initial evaluation should use clinical features, radiographic features, and occasionally quantitative models to determine the likelihood of malignancy. The likelihood of malignancy then determines further management, usually computed tomography (CT) surveillance or biopsy."

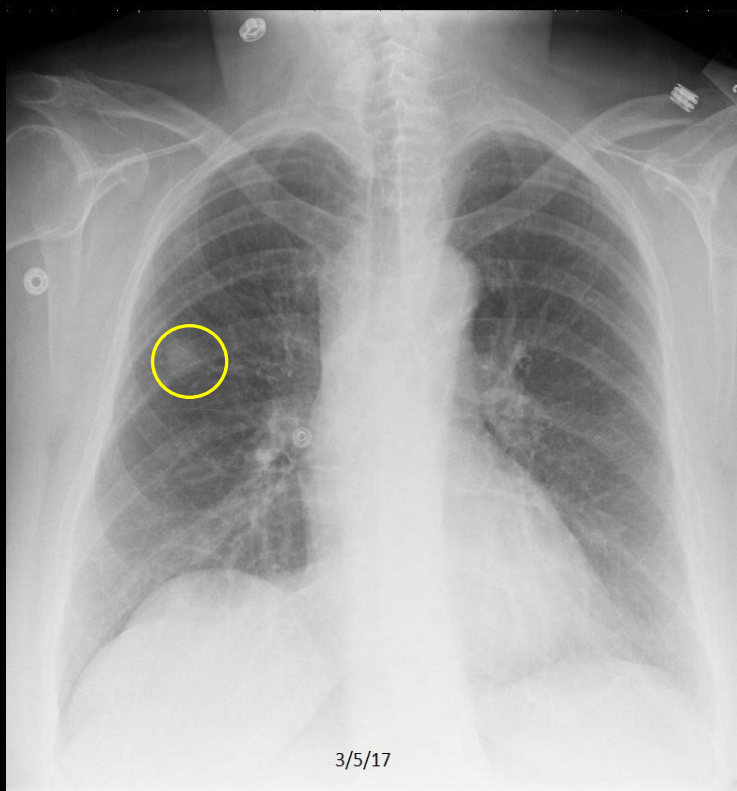
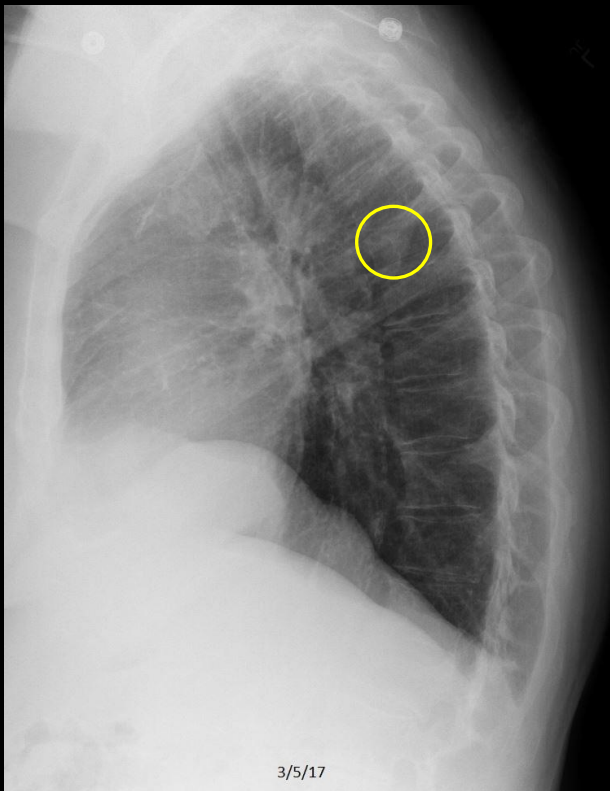
"The majority of incidentally nodules are benign."

"An incidental pulmonary nodule is benign if it demonstrates fat (pulmonary hamartoma) or a characteristic calcification pattern (e.g., granuloma, hamartoma) or if it is stable on CT for a defined period of time (i.e. > 2 years for solid and > 5 years for subsolid nodules."

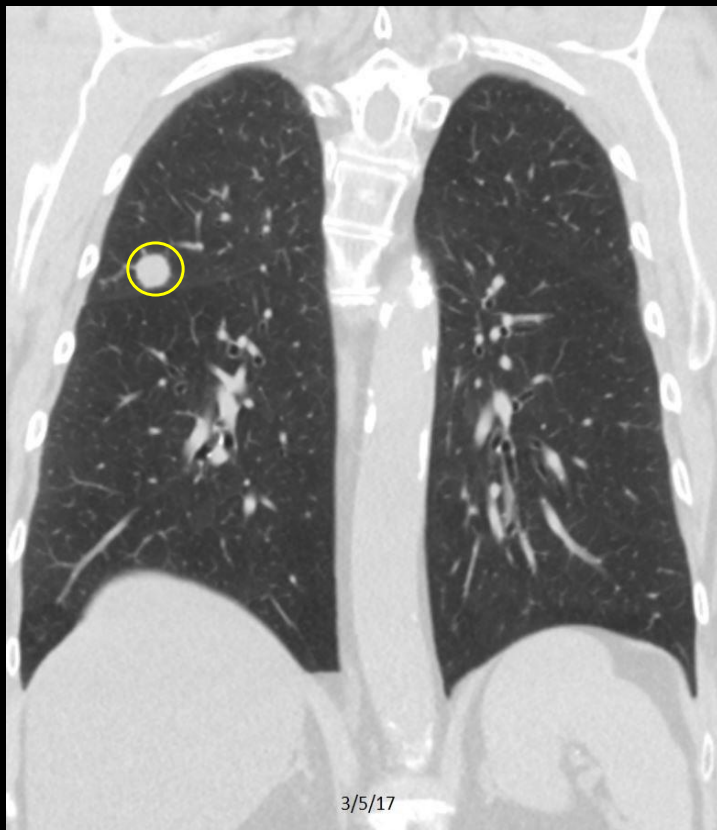
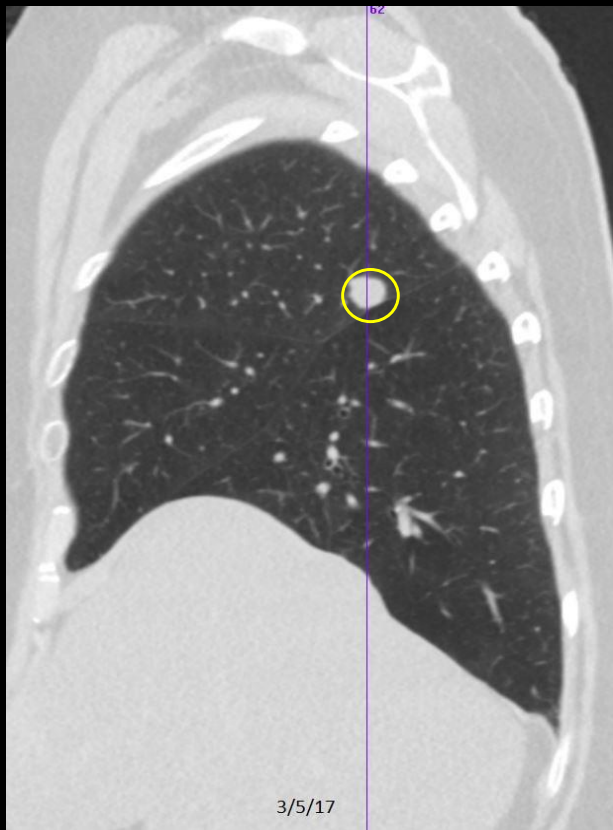
Weinberger SE, McDermott S. Diagnostic evaluation of the incidental pulmonary nodule. UpToDate, accessed 3/26/20 (last updated 6/21/19).



C349. 67 year old woman with dyspnea. Right pulmonary nodule.



C349. 67 year old woman with dyspnea. **Right pulmonary nodule.**



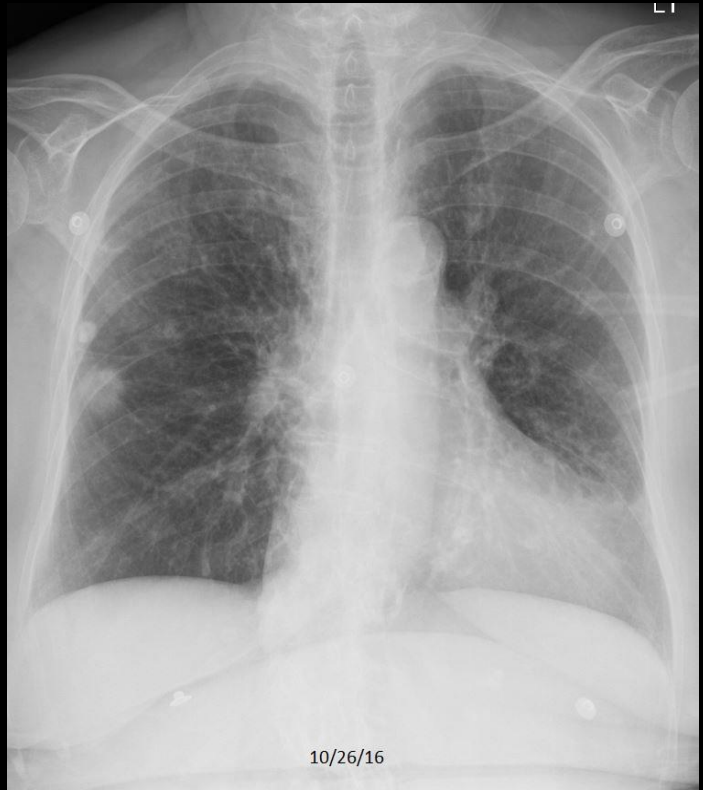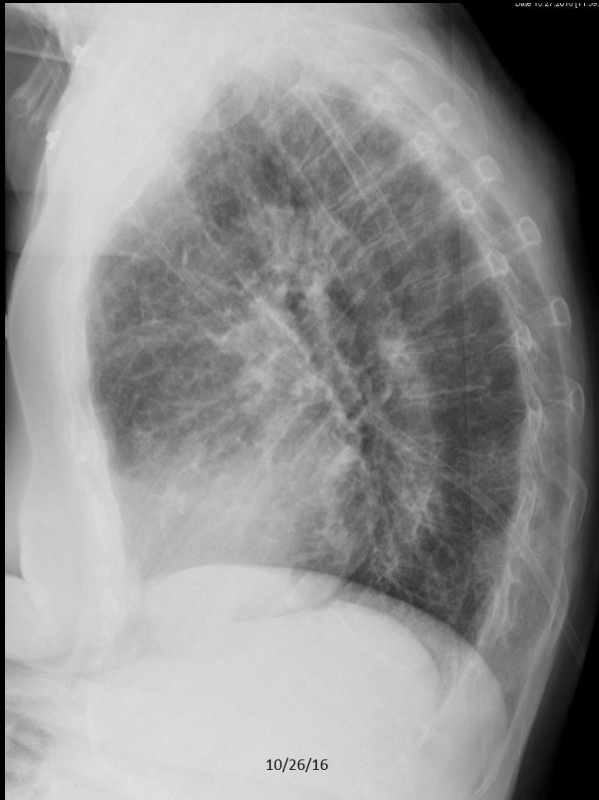C349. 67 year old woman with dyspnea. **Right pulmonary nodule.** Incidentally discovered lung cancer.

# **PULMONARY NODULES**

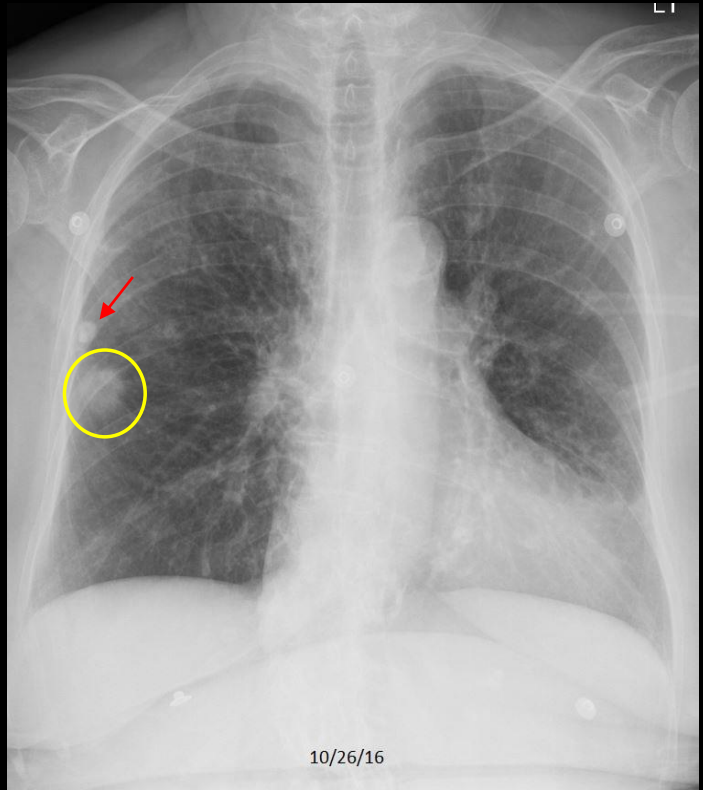
## **EXAMPLES**

### **CR ONLY**

# Example 1 of 10

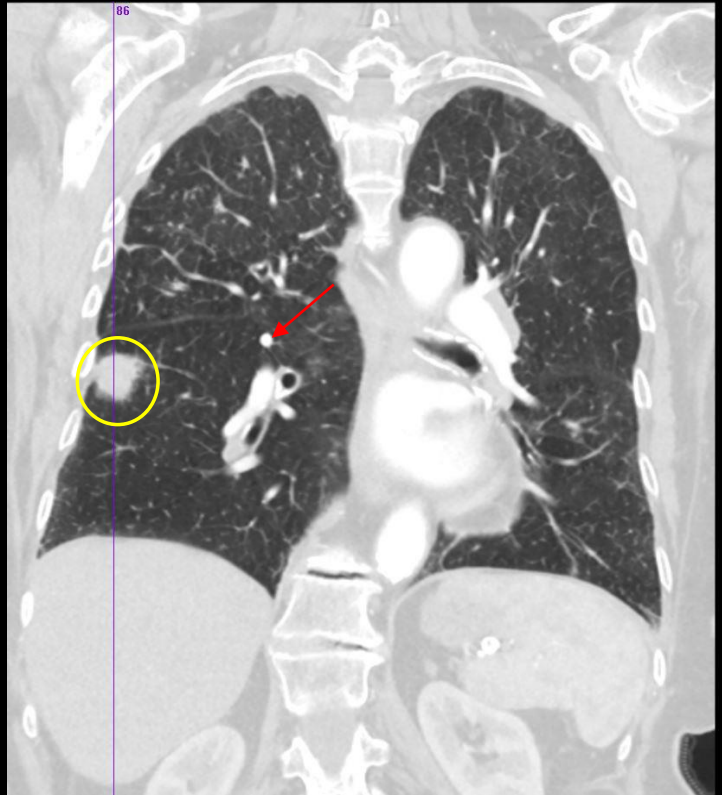
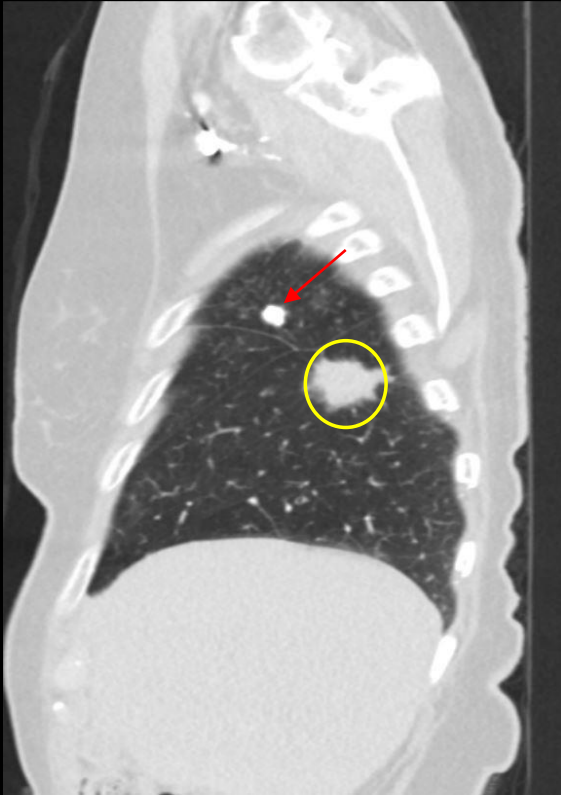


# Example 1 of 10



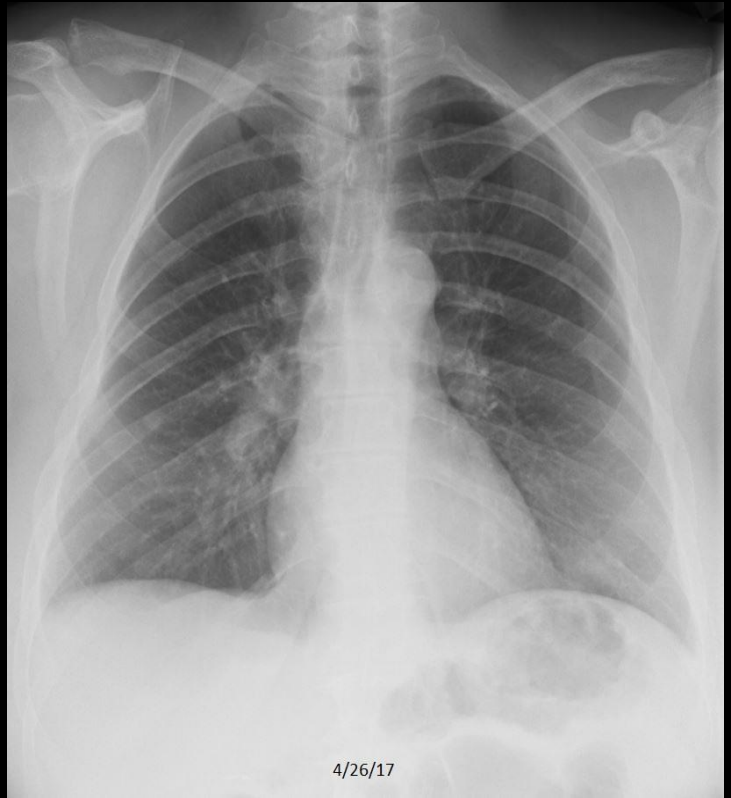
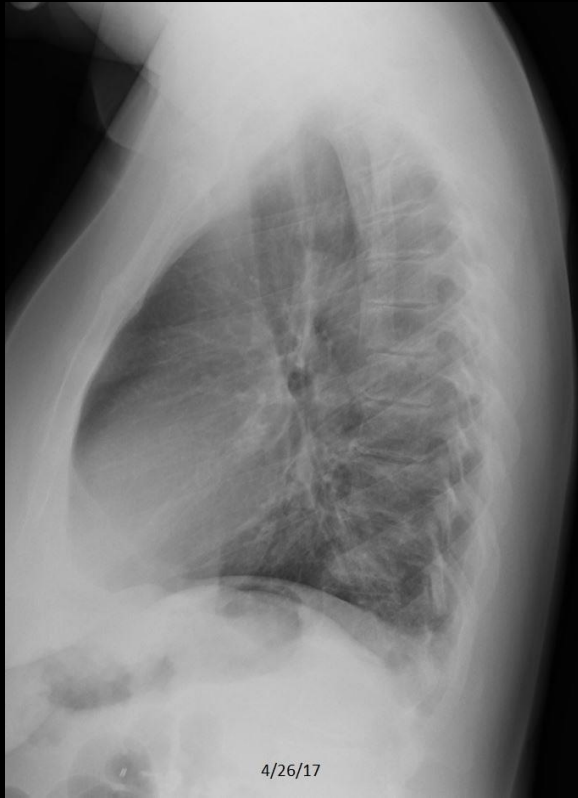C286. 84 year old woman with cough and dyspnea. **Right pulmonary nodule** and **calcified granuloma**.

## Example 1 of 10

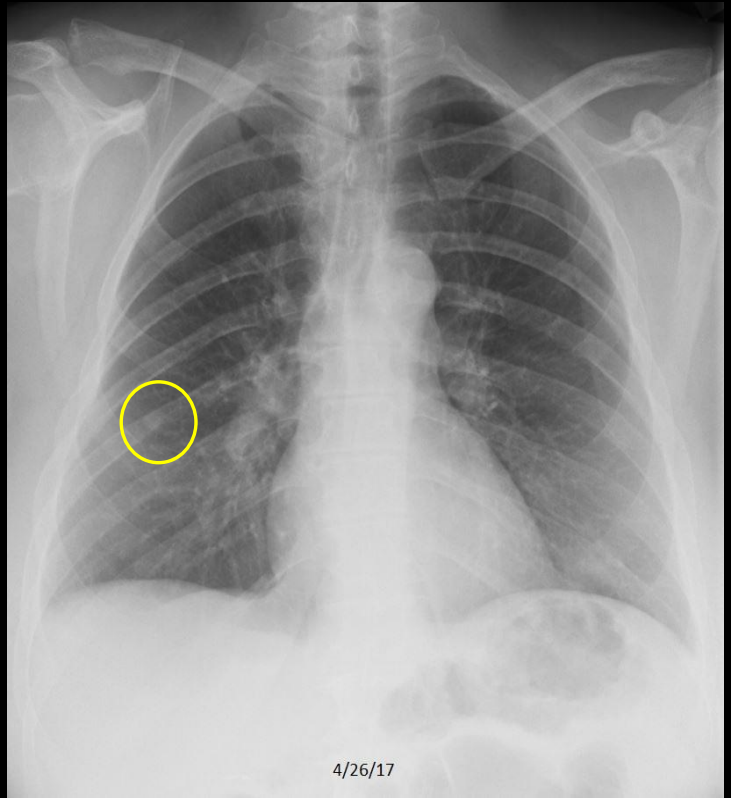


C286. 84 year old woman with cough and dyspnea. Right pulmonary nodule and **calcified granulomas**. Presumed lung cancer, although the patient declined biopsy or further work-up.

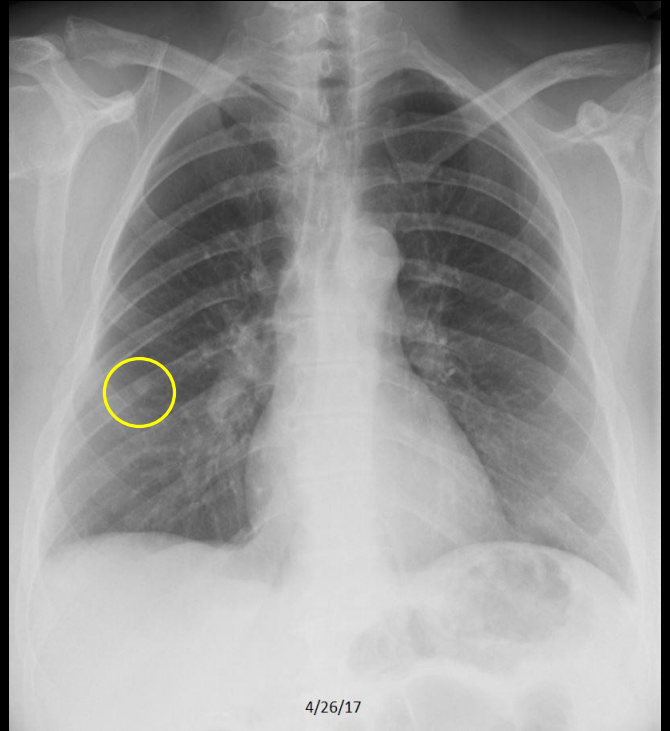
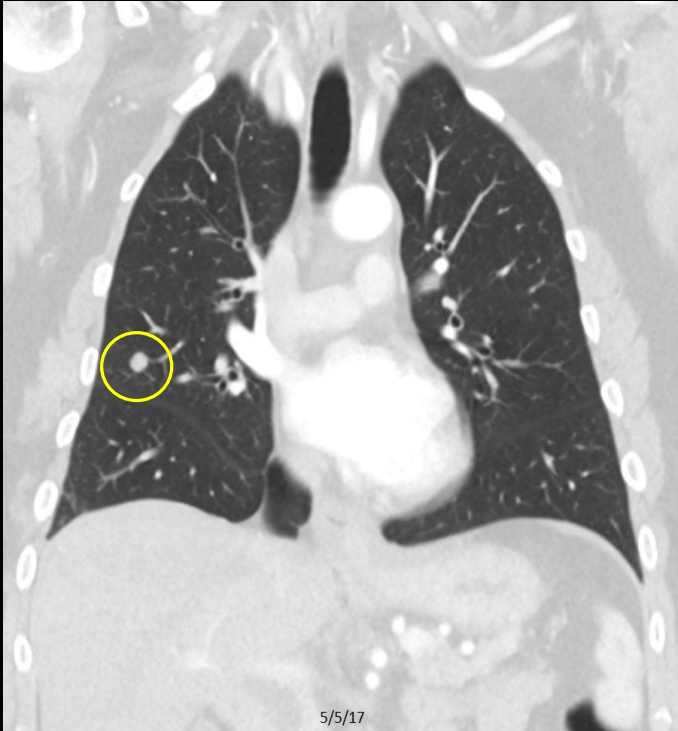## Example 2 of 10



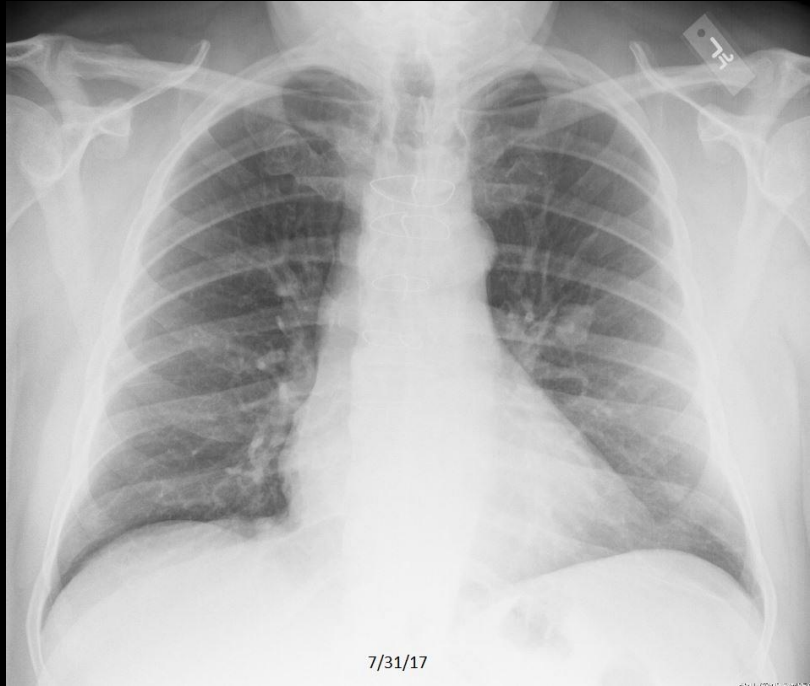
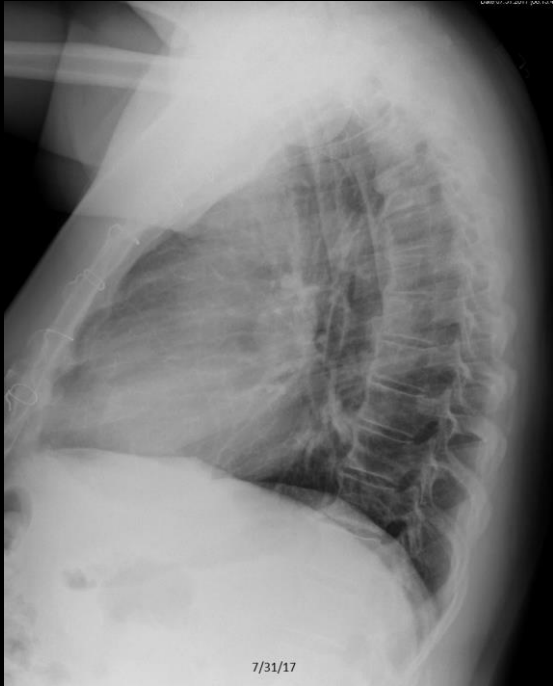## Example 2 of 10



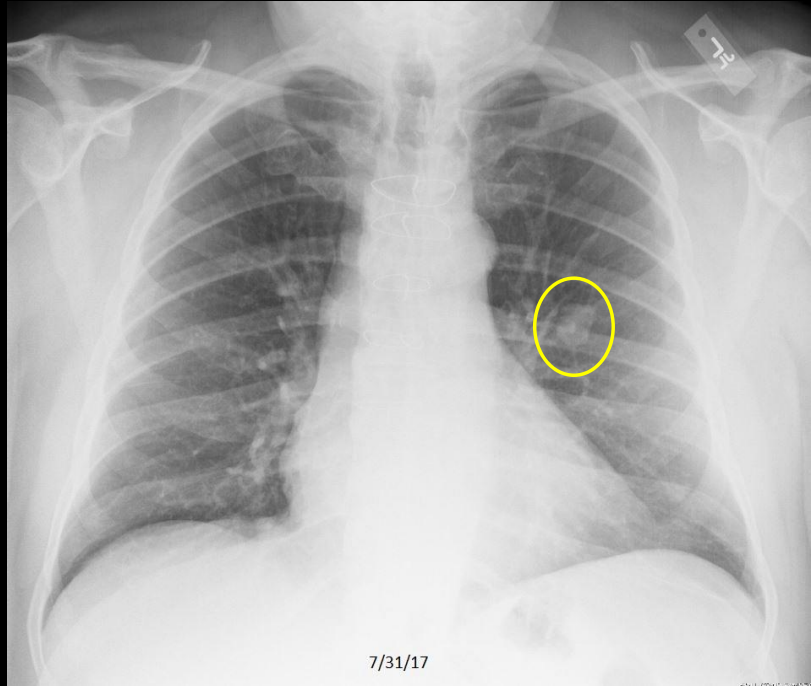
## Example 2 of 10



## Example 3 of 10

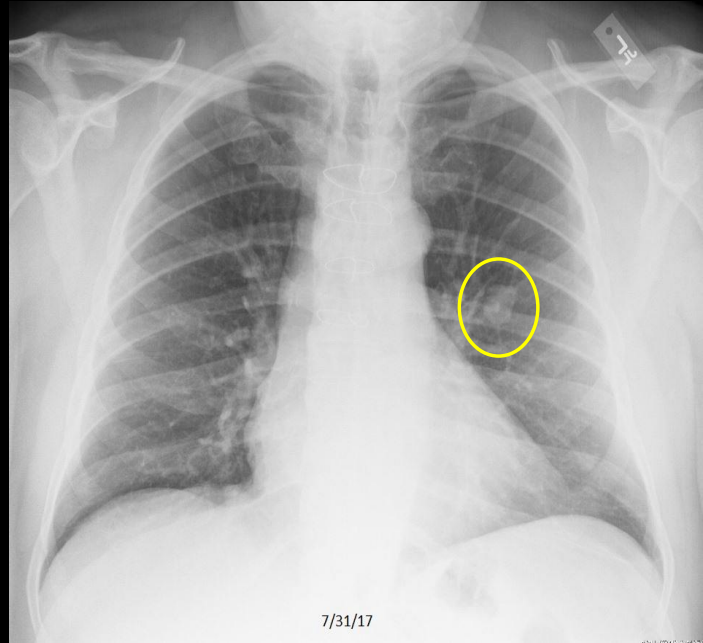
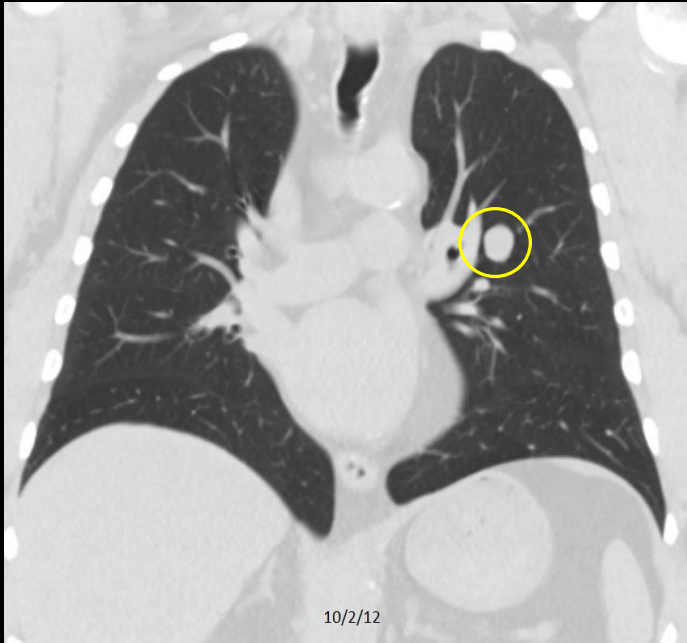


# Example 3 of 10



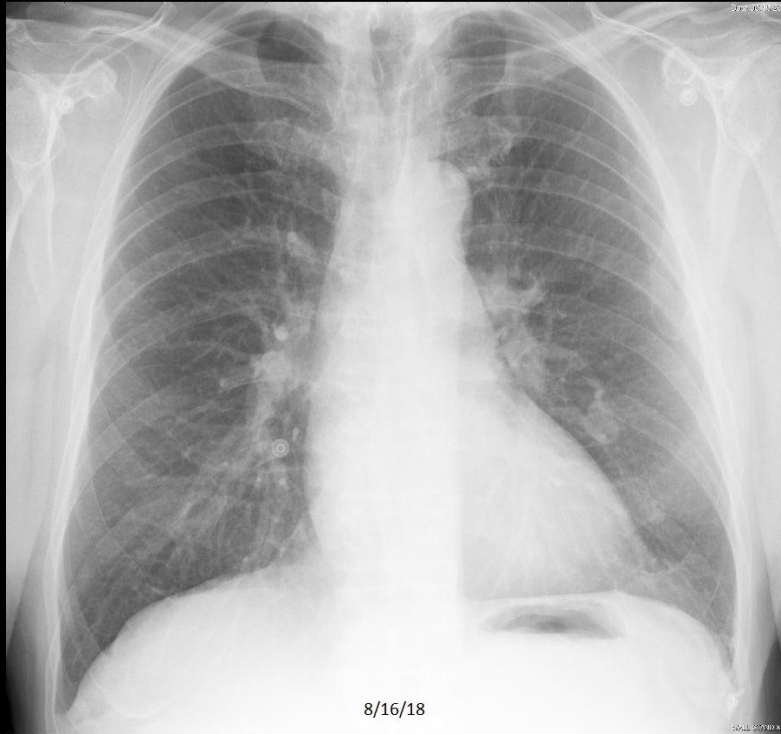
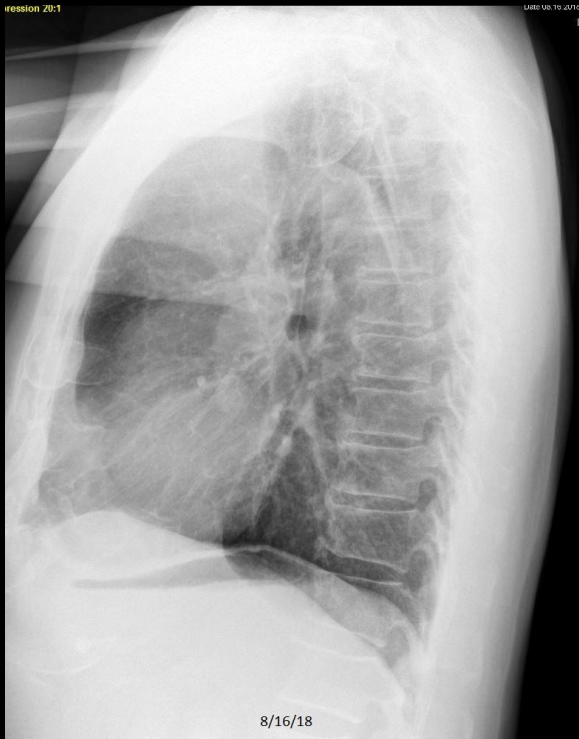
C467. 65 year old man with cough. Left pulmonary nodule.

## Example 3 of 10

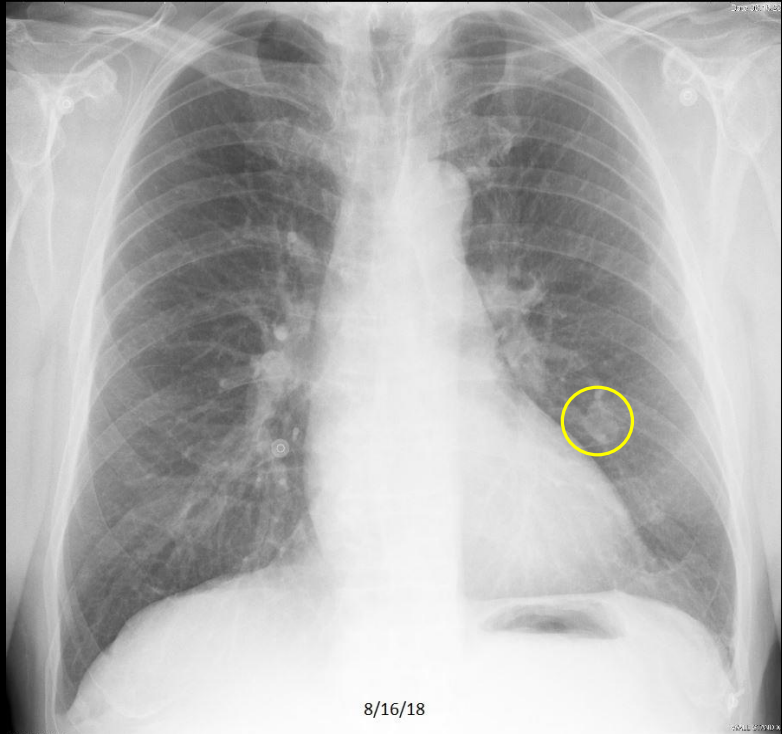
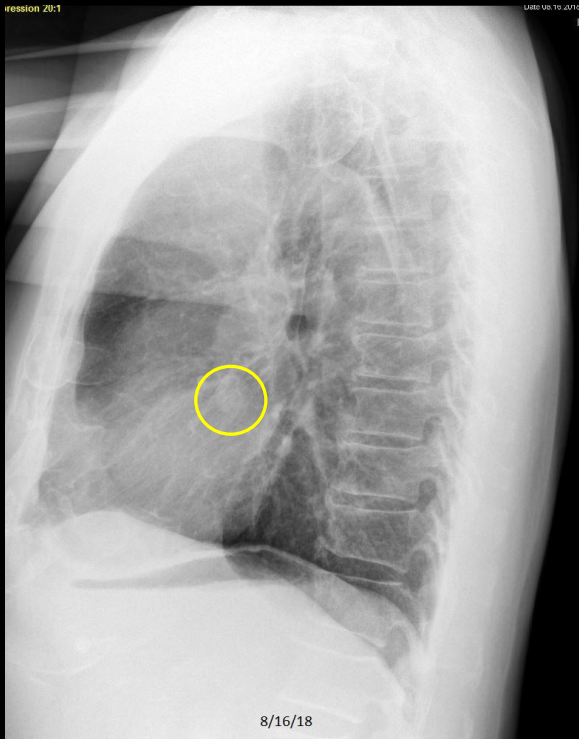


C467. 65 year old man with cough. Left pulmonary nodule. Benign hamartoma.

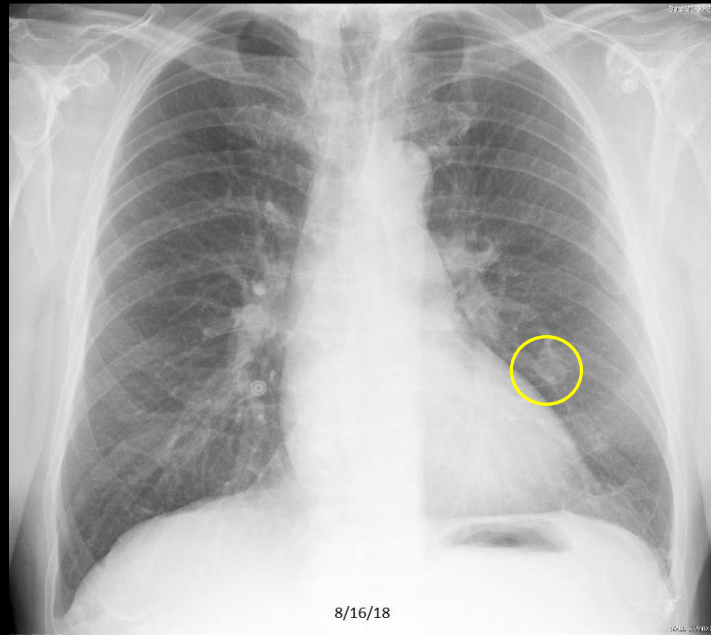
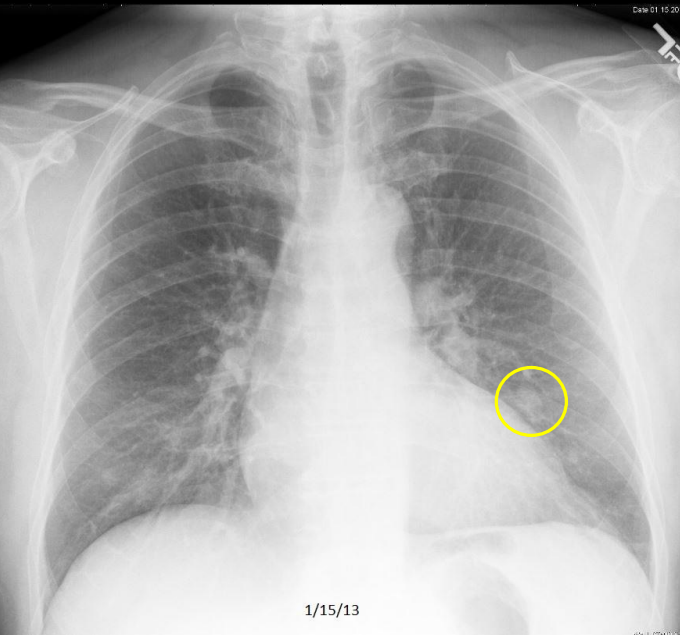
## Example 4 of 10



## Example 4 of 10

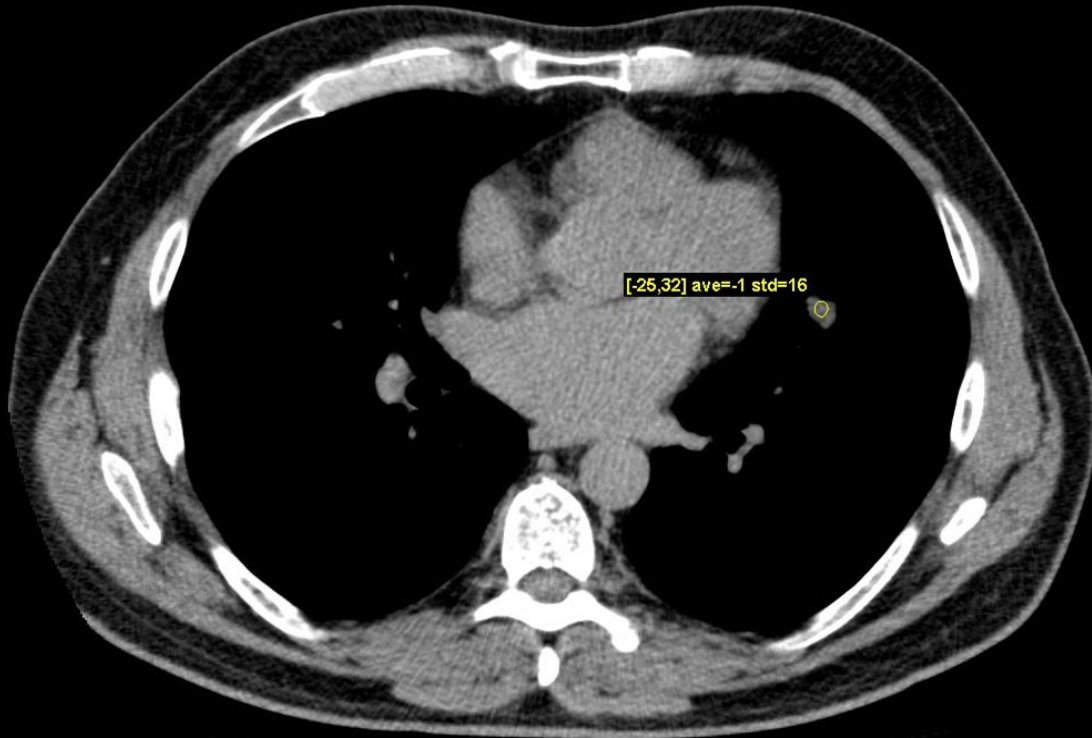


## Example 4 of 10



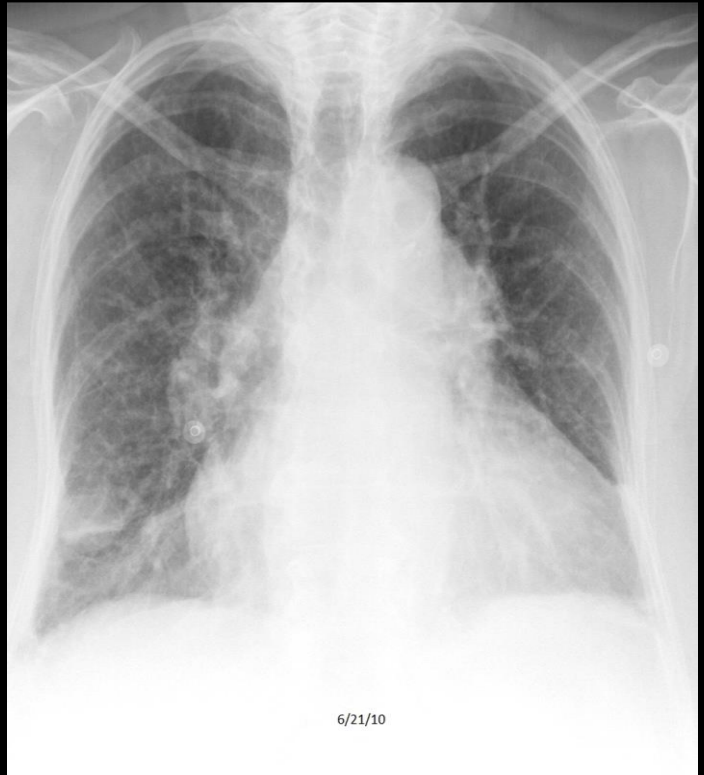
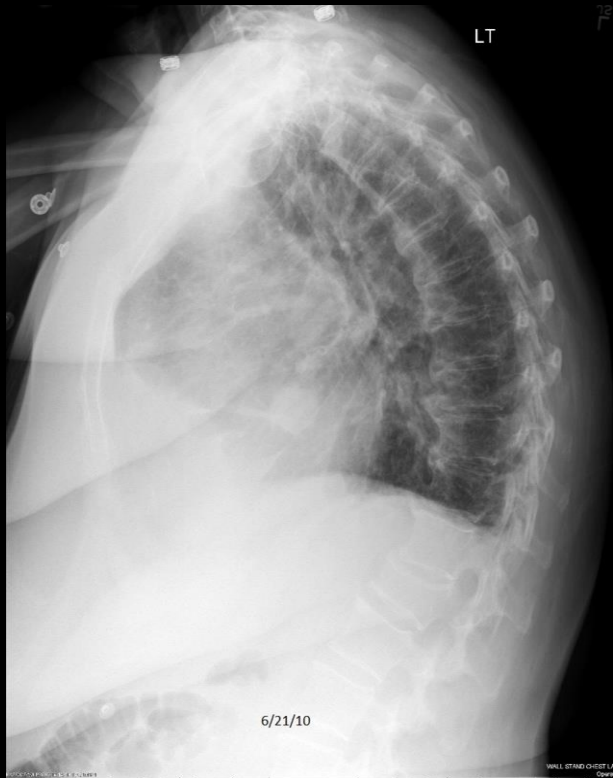C486. 57 year old man with dyspnea. Left pulmonary nodule. Stable from prior study.

## Example 4 of 10



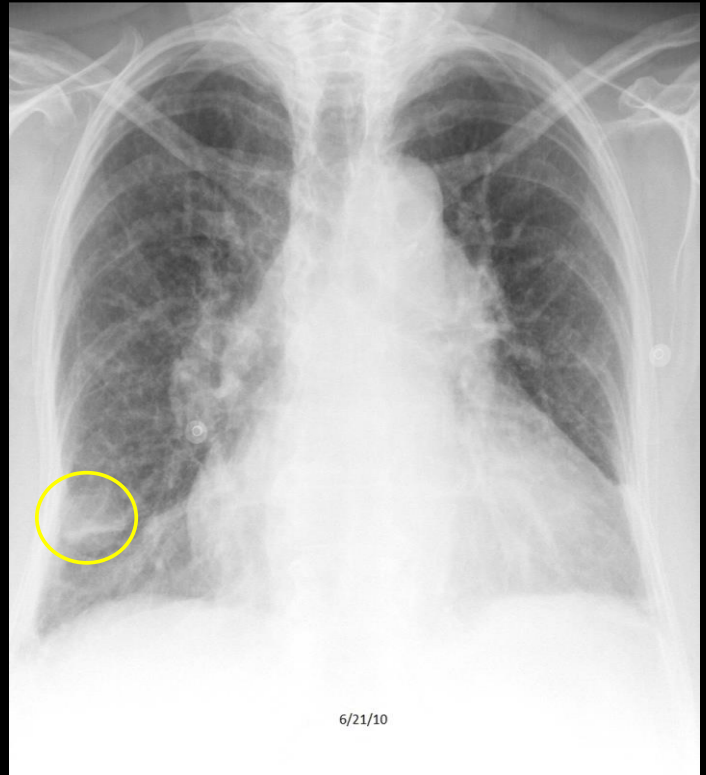
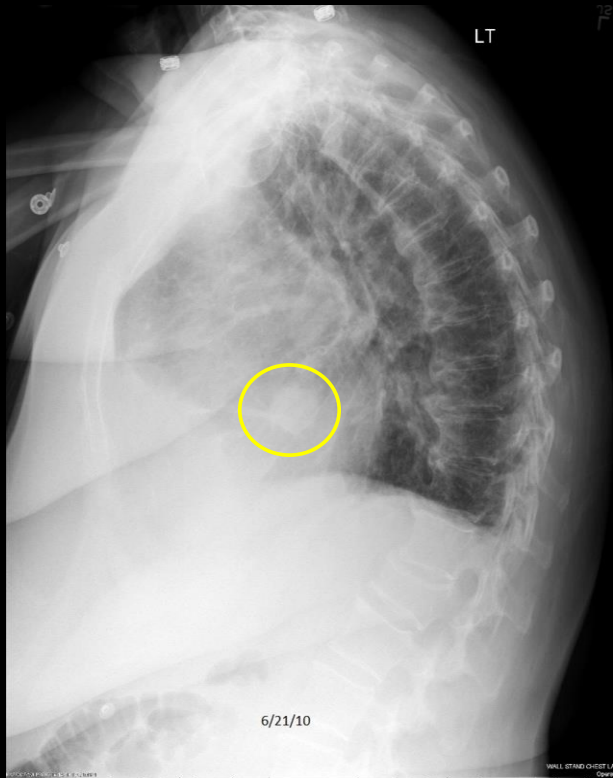
3/5/14

## Example 5 of 10



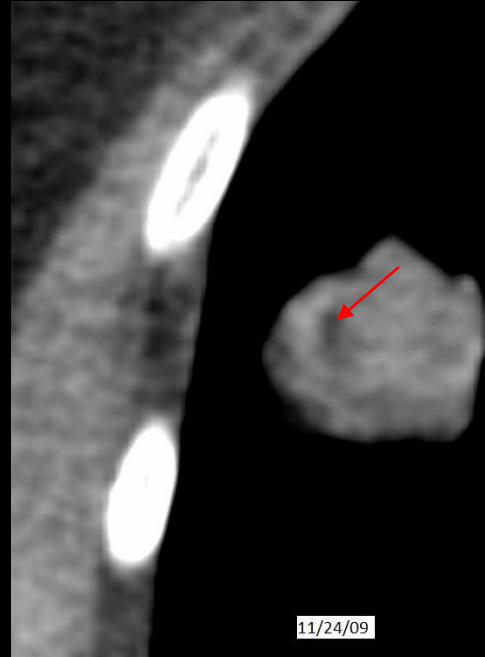
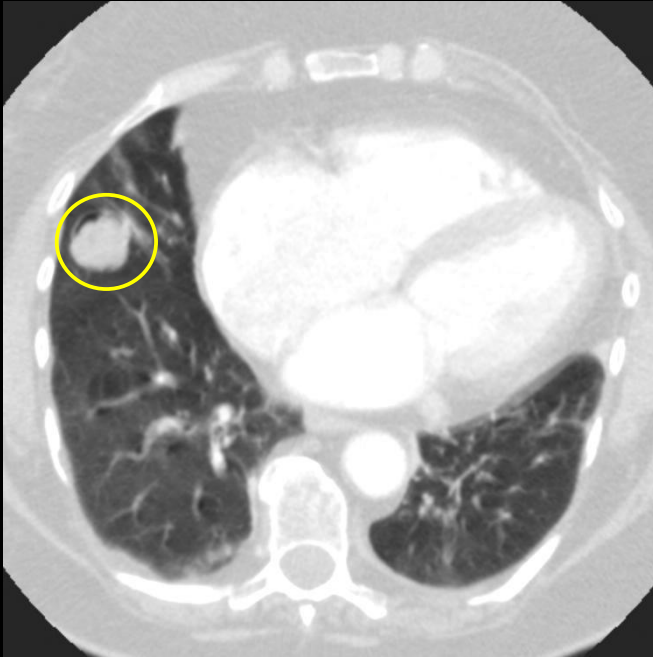
C487. 74 year old with pain following injury. Right pulmonary nodule. Chronic congestive heart failure.

## Example 5 of 10



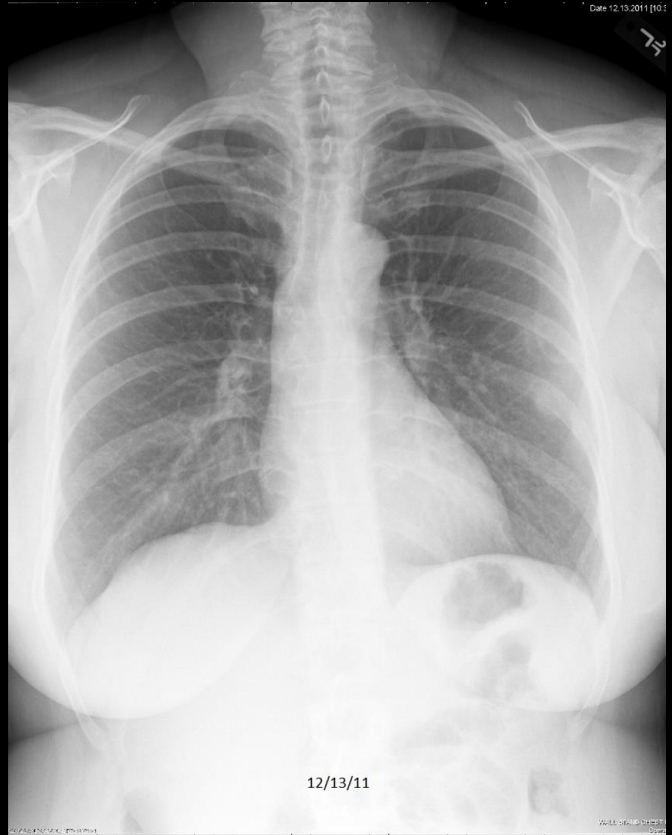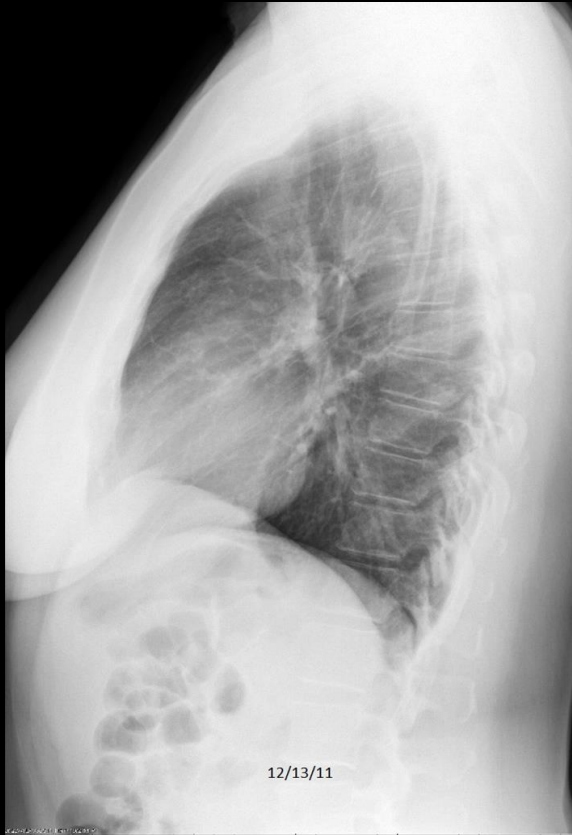C487. 74 year old with pain following injury. **Right pulmonary nodule**. Congestive heart failure with cardiomegaly, diffuse increased lung density, pulmonary vascular redistribution, and pleural effusions.

## Example 5 of 10

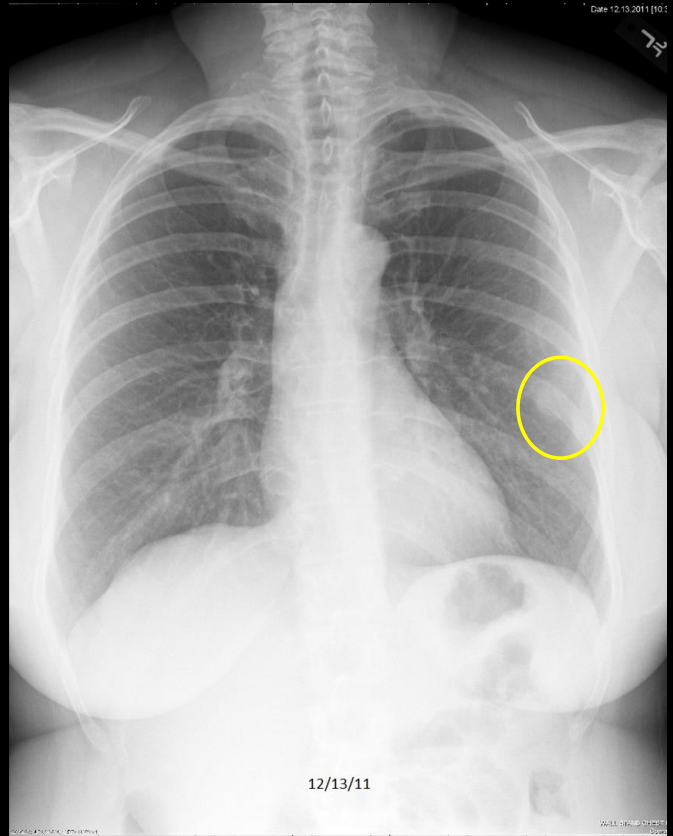
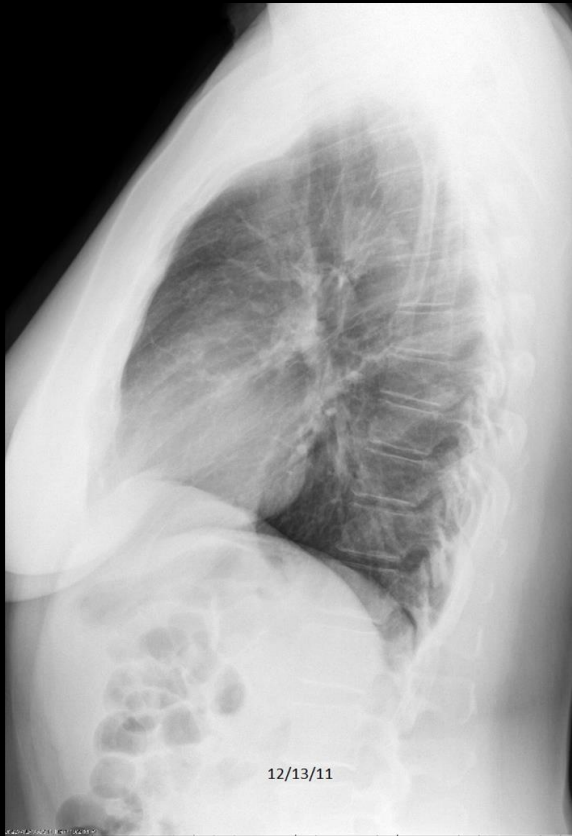

11/24/09

## Example 6 of 10

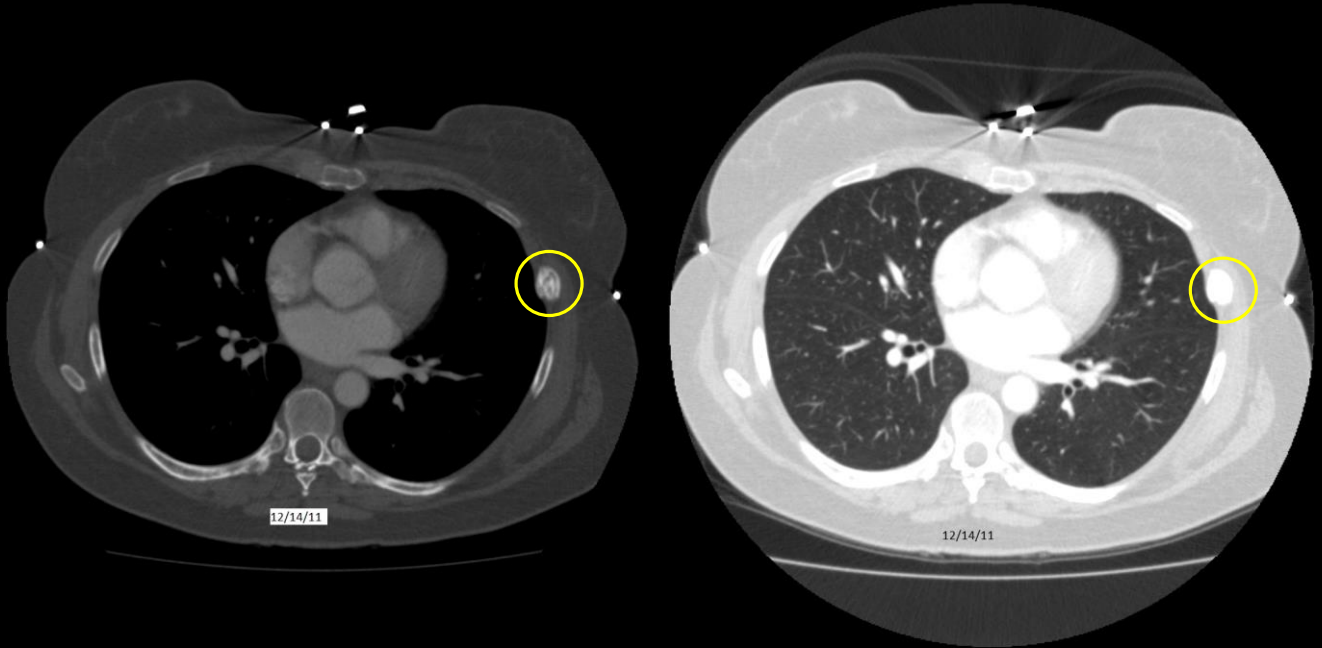


## Example 6 of 10



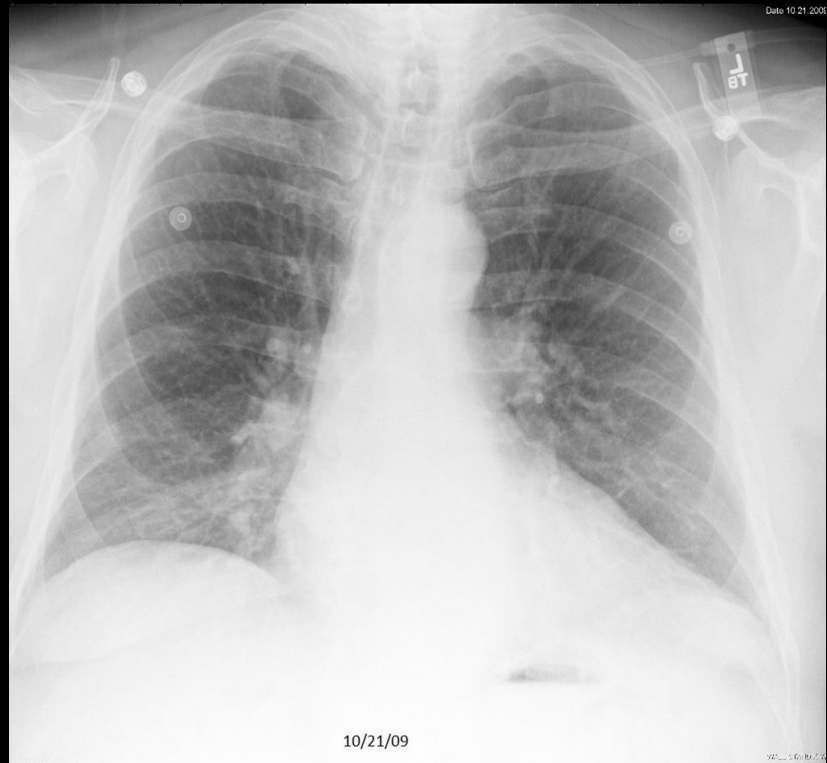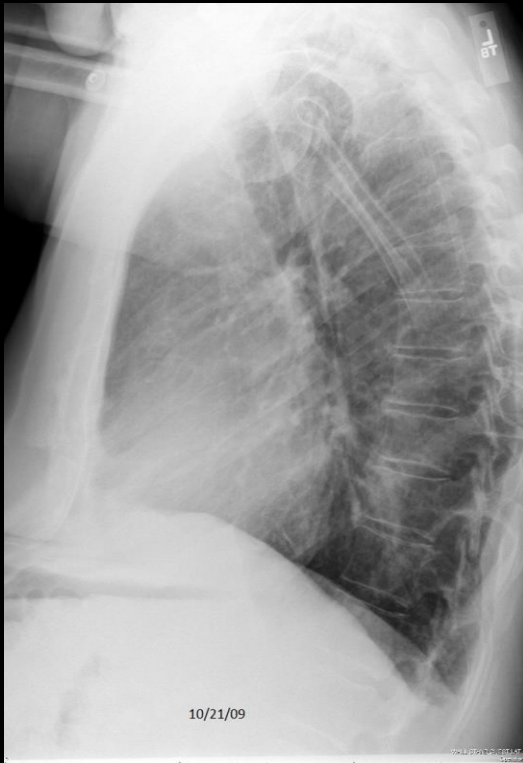C488. 56 year old woman with cough. **Left pulmonary nodule.**

## Example 6 of 10

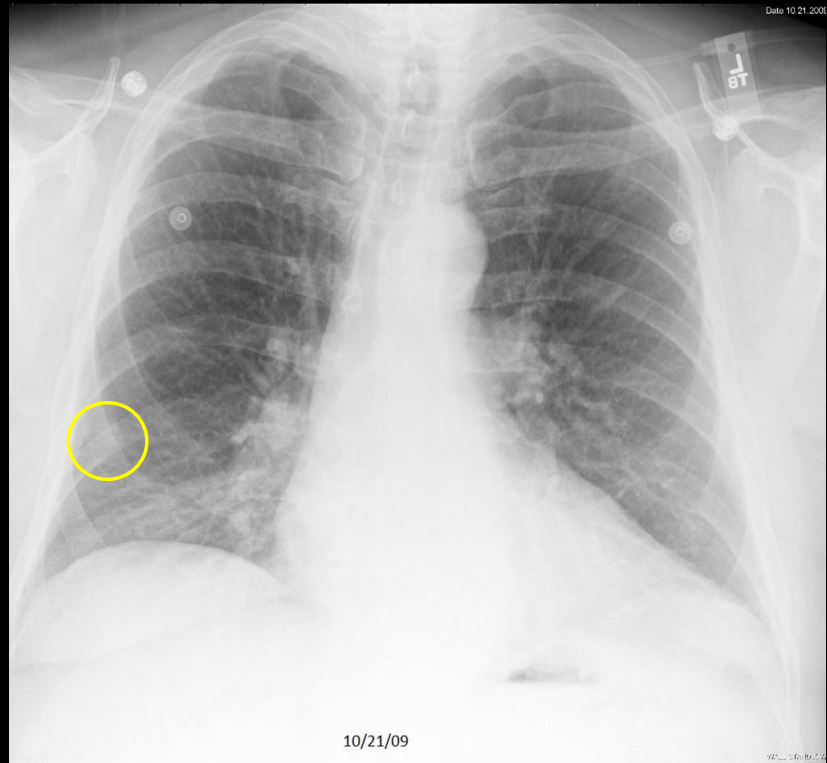


C488. 56 year old woman with cough. Left pulmonary nodule. Pseudonodule caused by healing rib fracture.

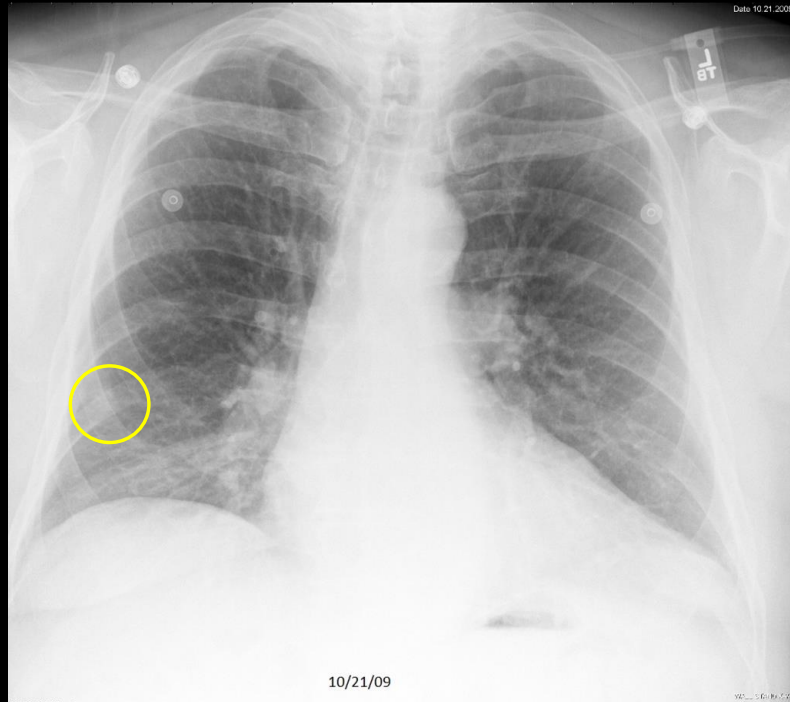
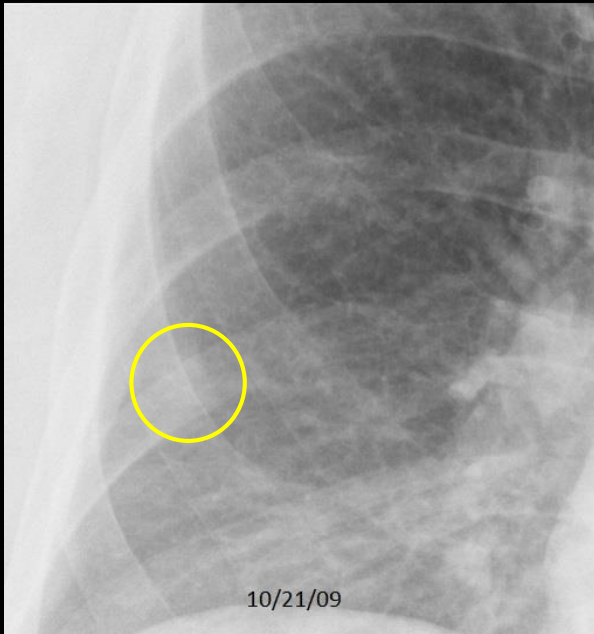
## Example 7 of 10



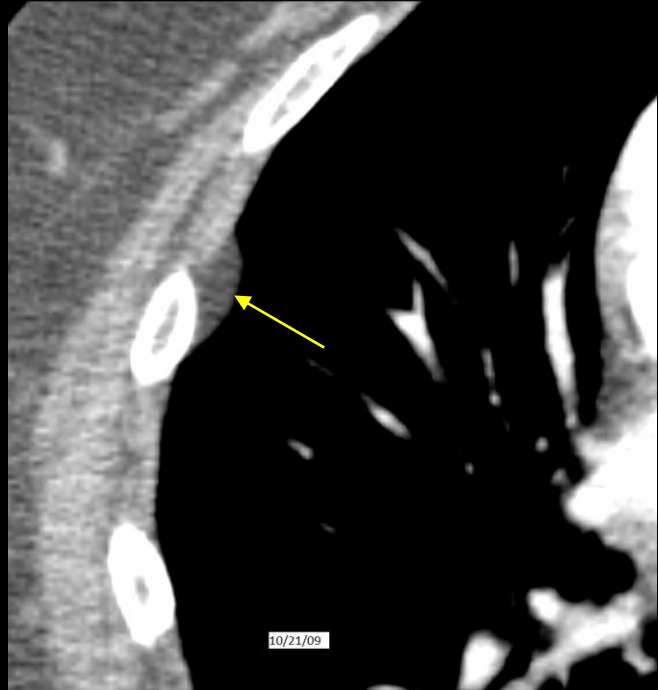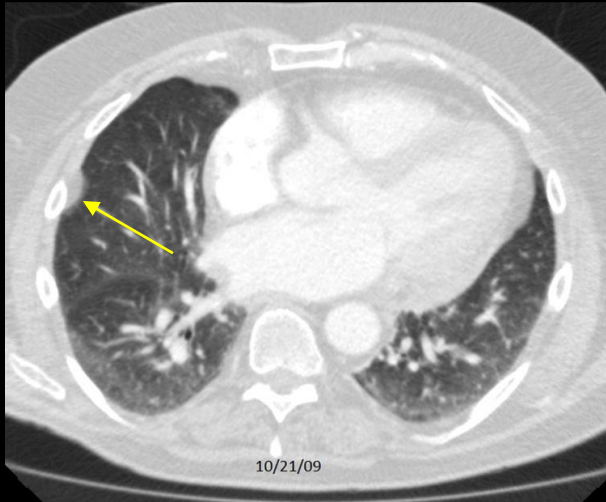
## Example 7 of 10



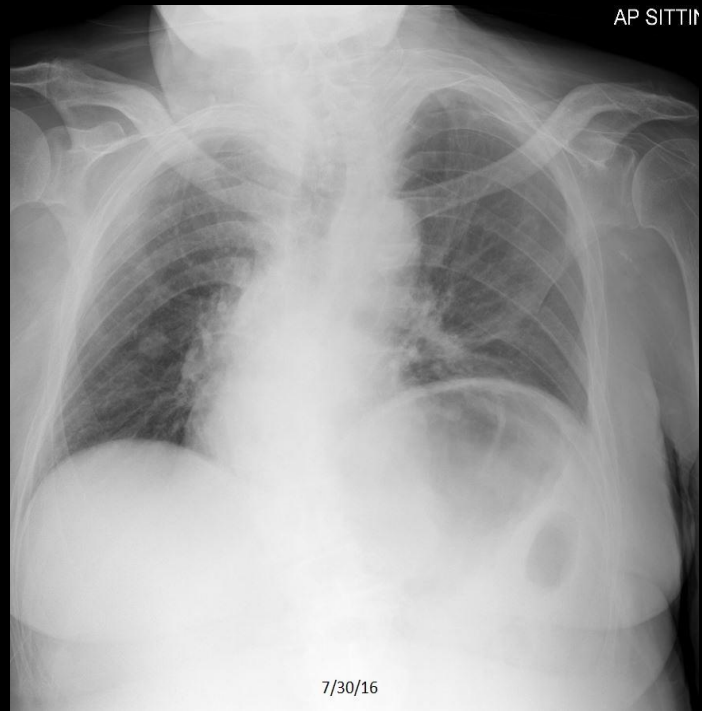
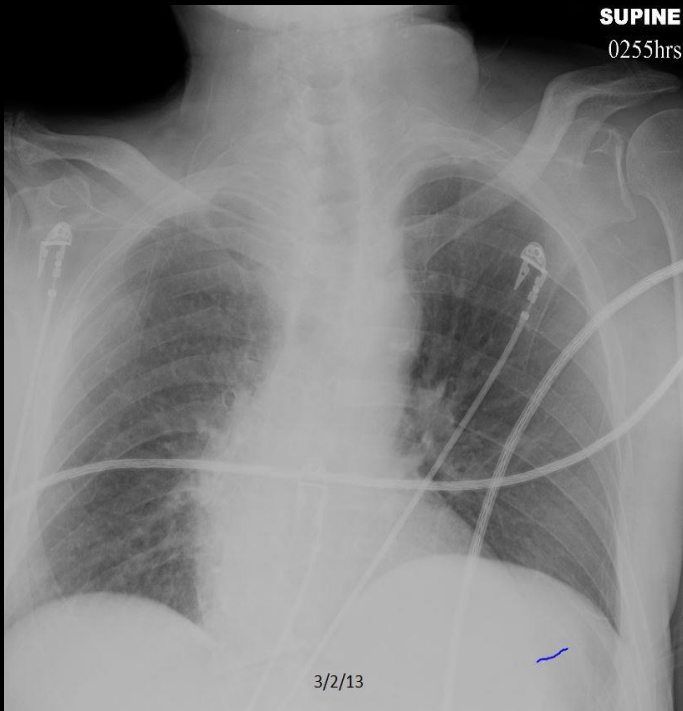
# Example 7 of 10



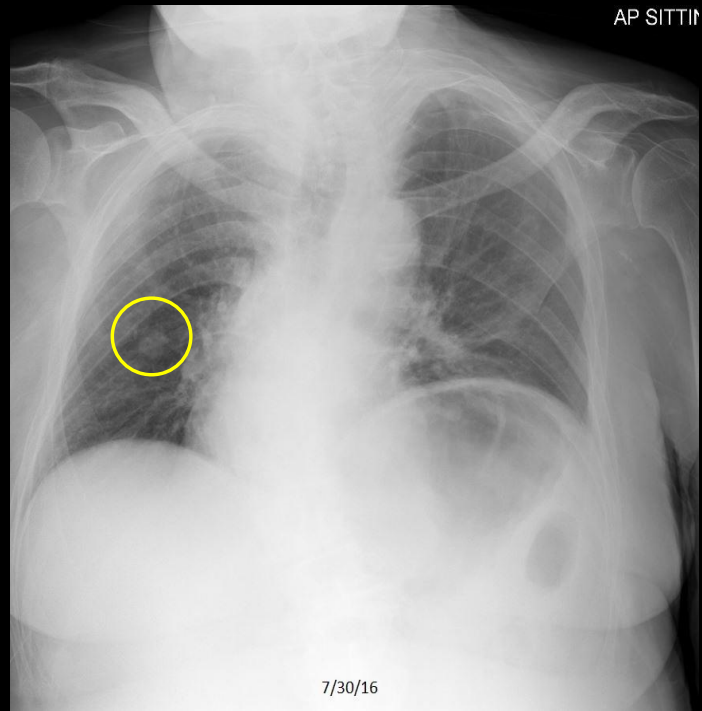
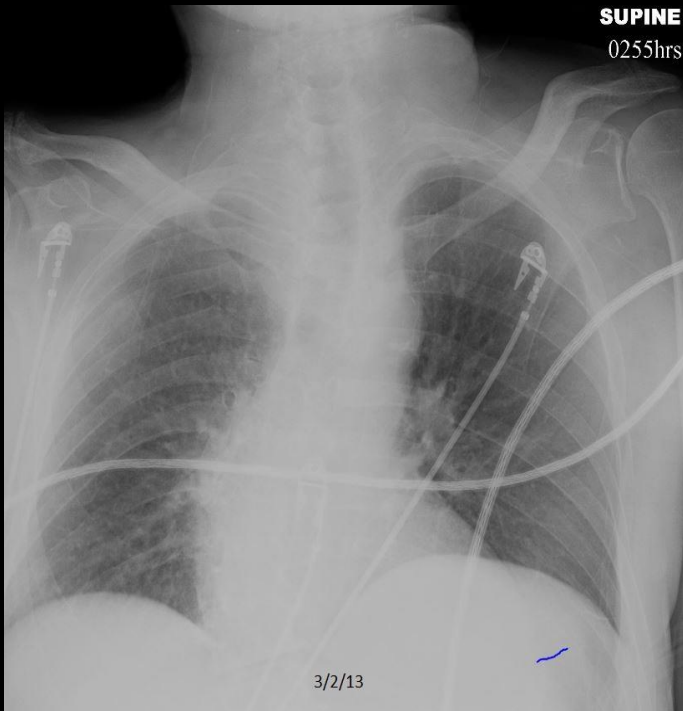
## Example 7 of 10



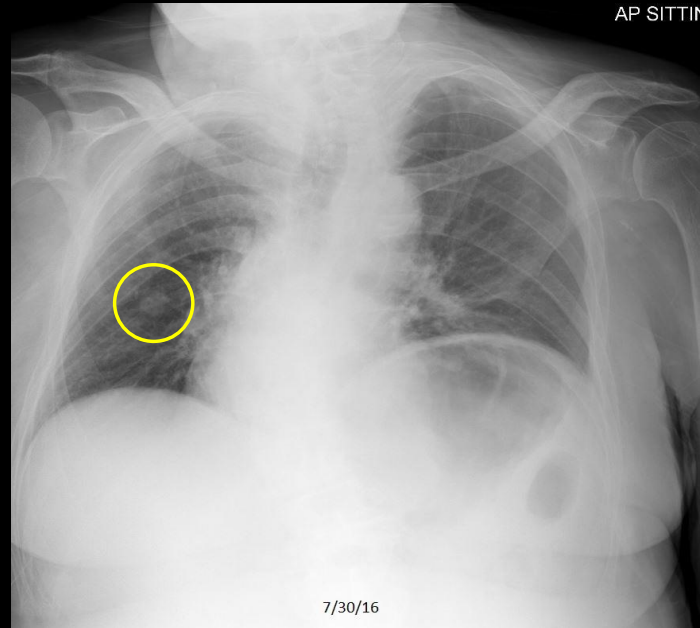
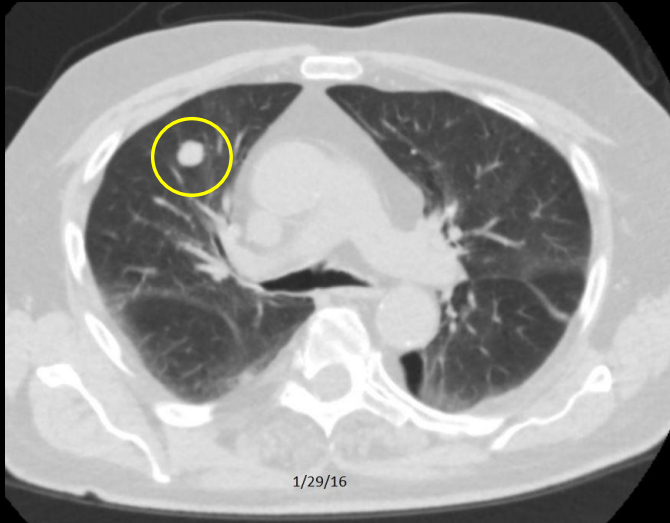
# Example 7 of 10



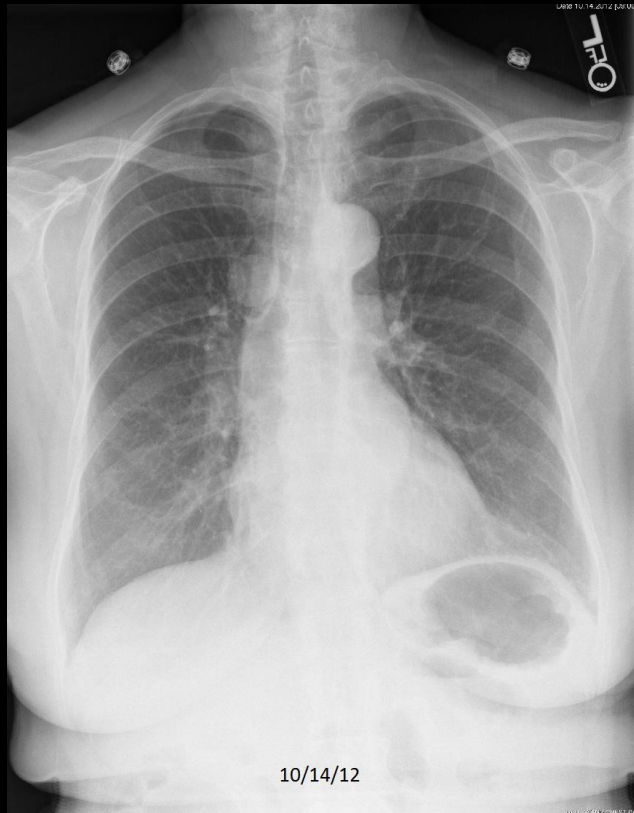# Example 7 of 10



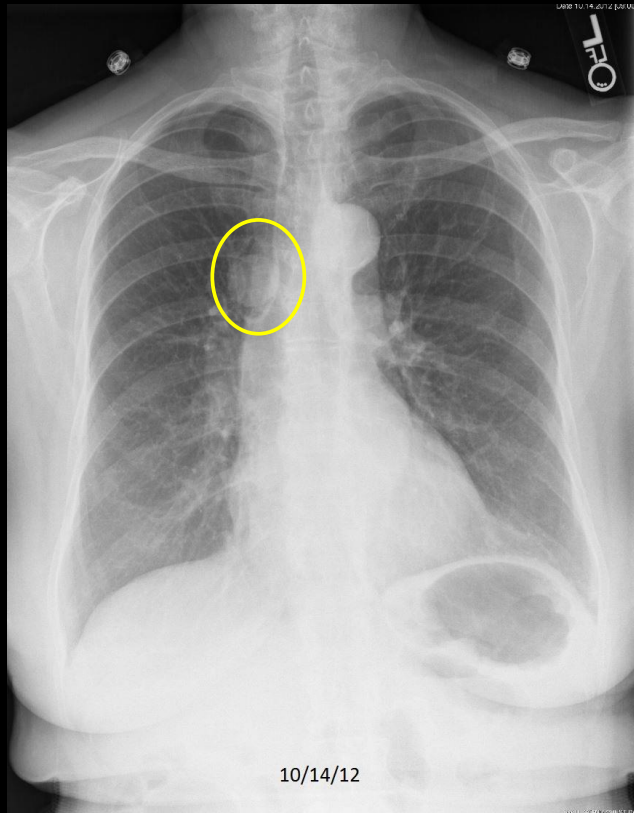
## Example 7 of 10



## Example 8 of 10

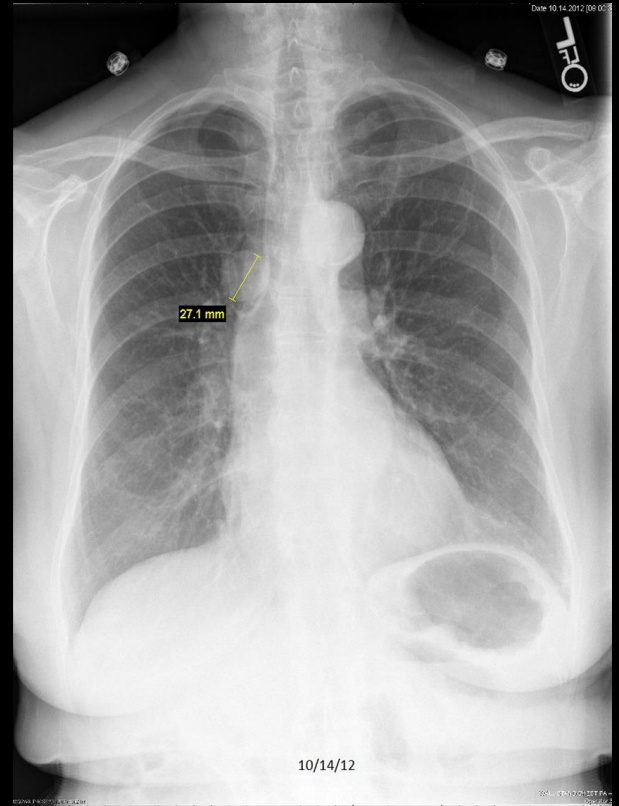
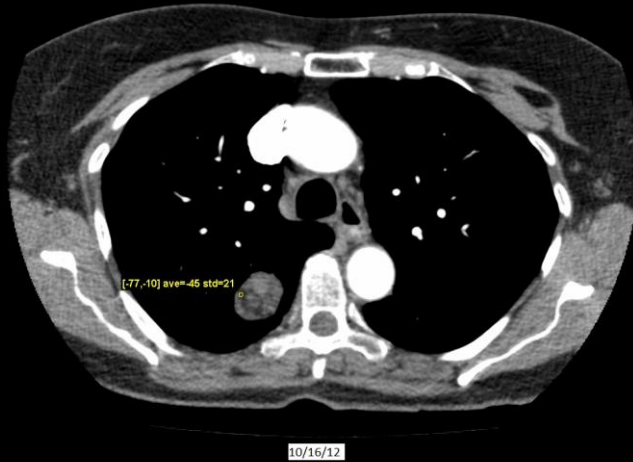


## Example 8 of 10



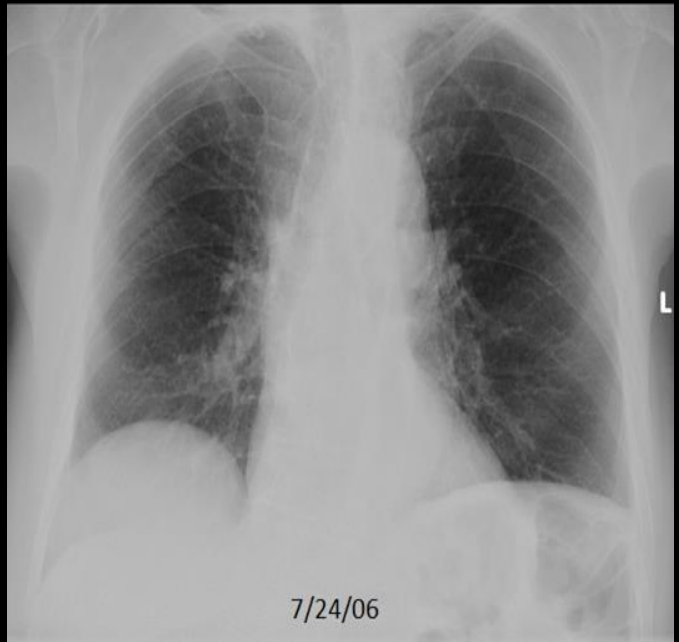
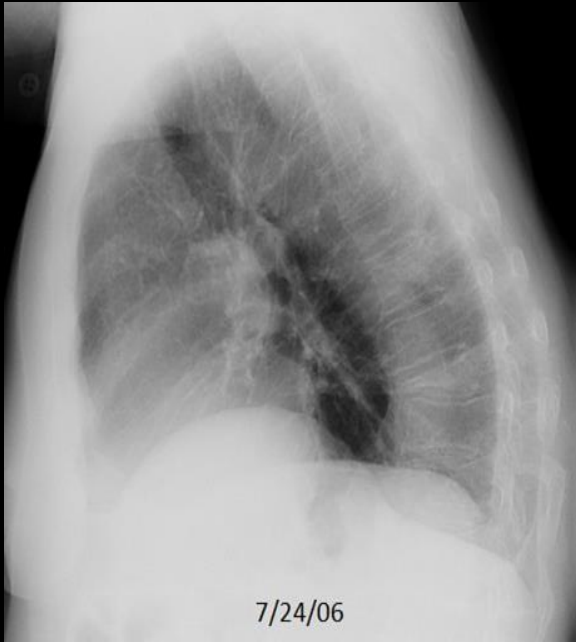C497. 75 year old woman with rib pain following injury sustained in a fall. **Right pulmonary nodule** on chest component of the exam.

## Example 8 of 10

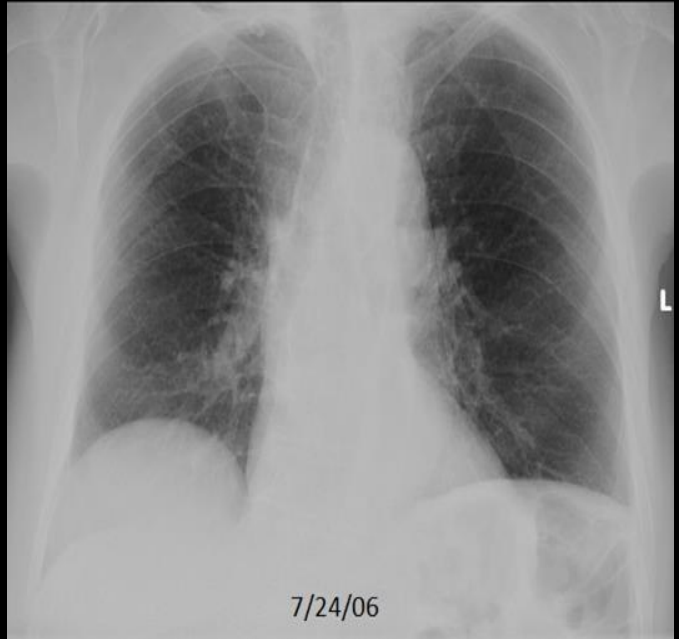
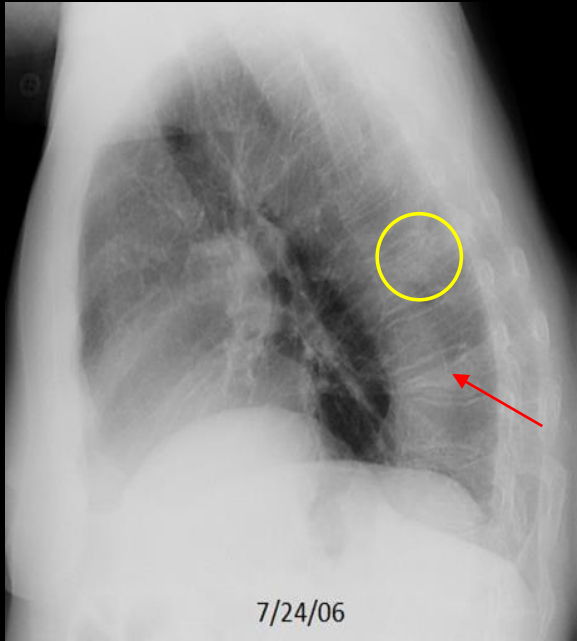


C497. 75 year old woman with rib pain following injury sustained in a fall. **Right pulmonary nodule** on chest component of the exam. **Intralesional fat** in keeping with pulmonary hamartoma.

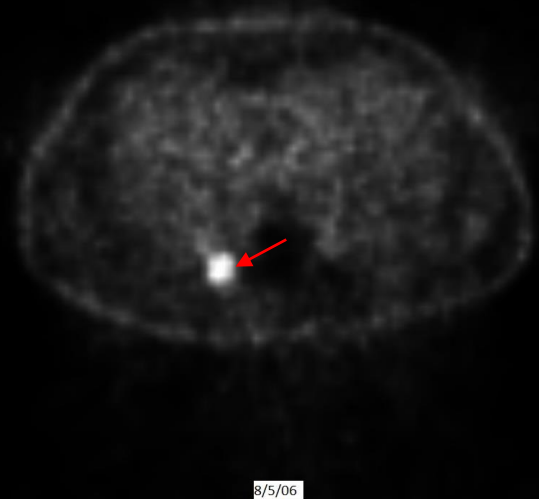
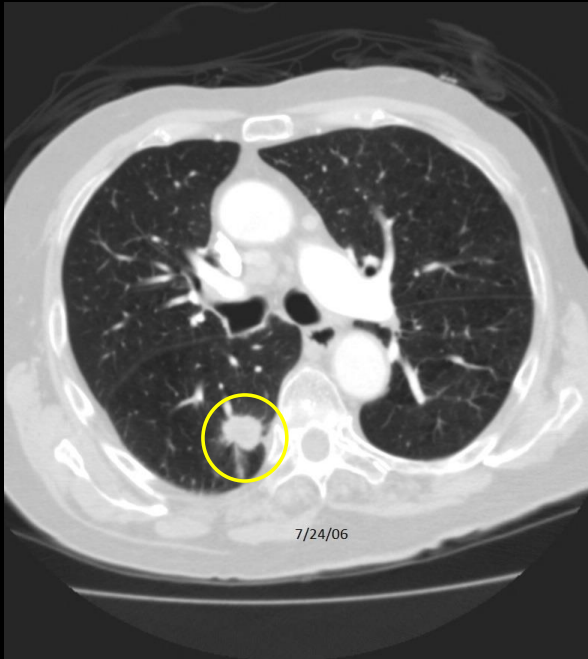
## Example 9 of 10



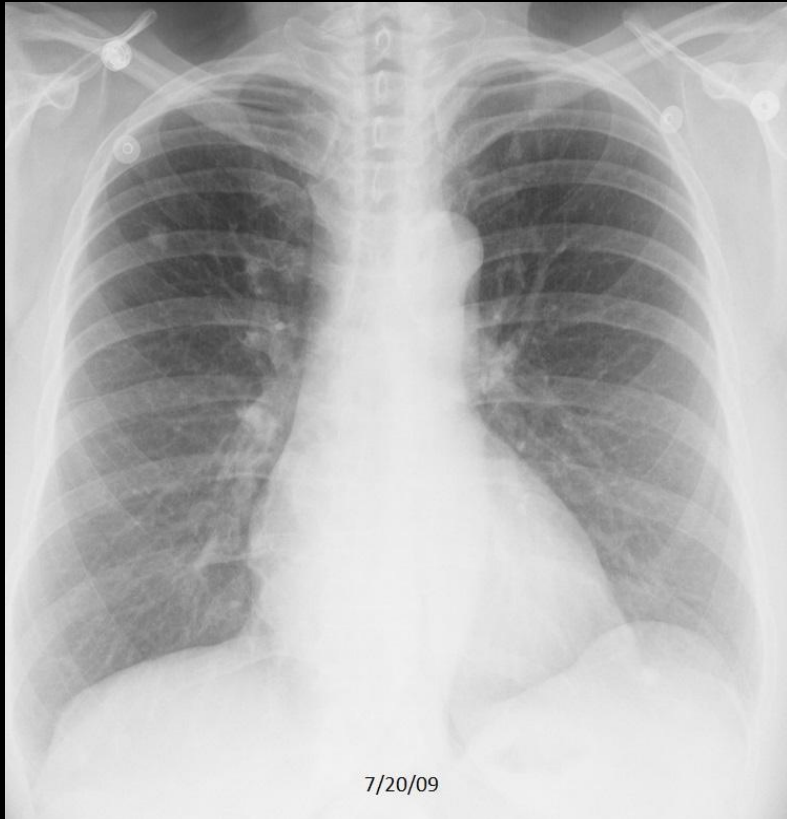
## Example 9 of 10



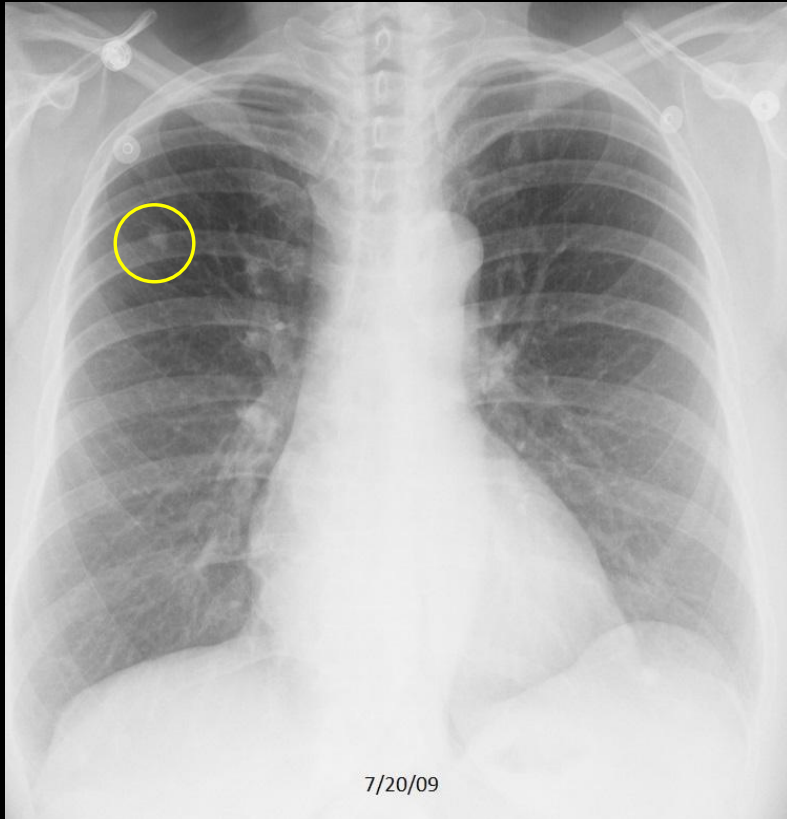
## Example 9 of 10



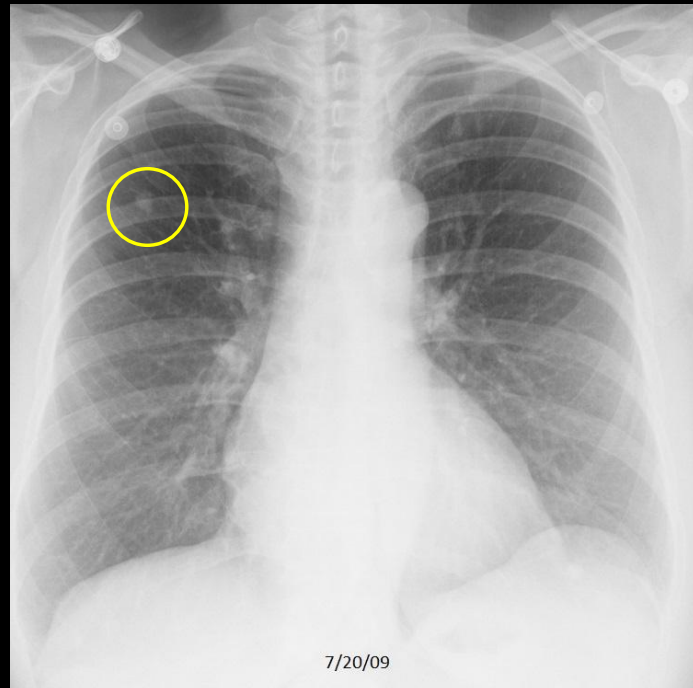
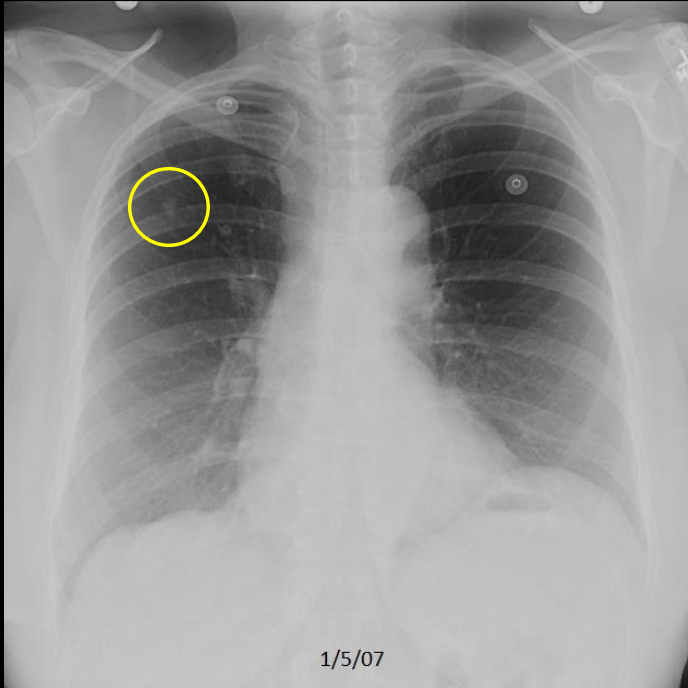
# Example 10 of 10



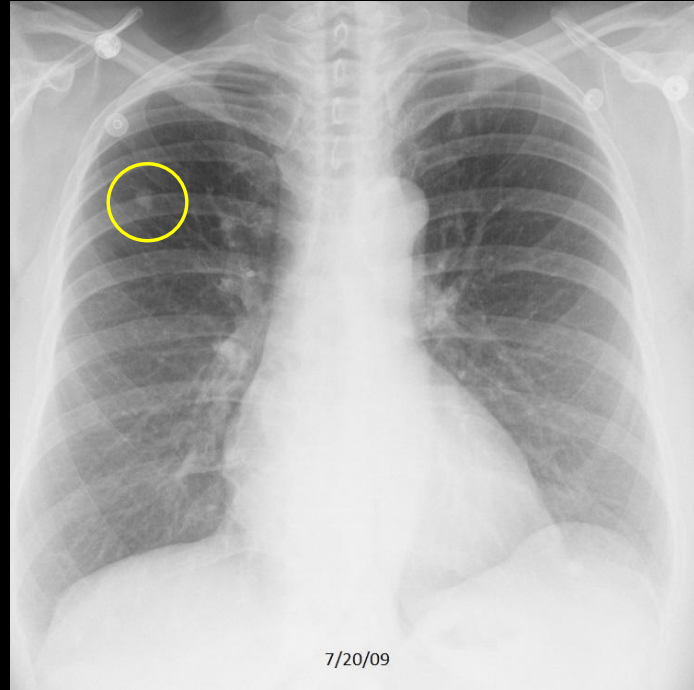
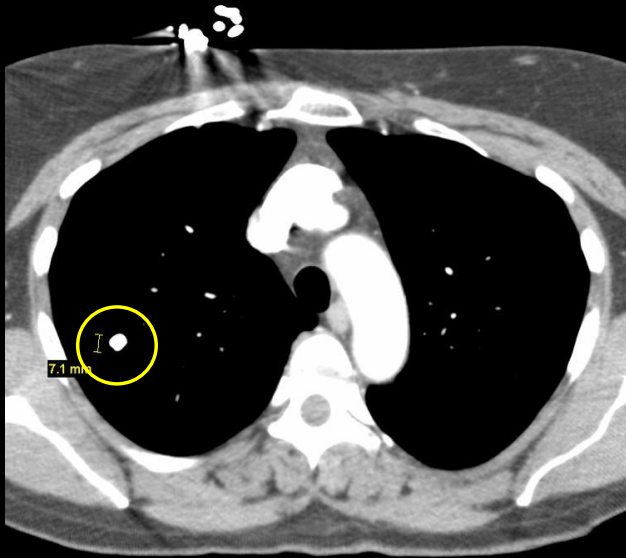
# Example 10 of 10



# Example 10 of 10



# Example 10 of 10

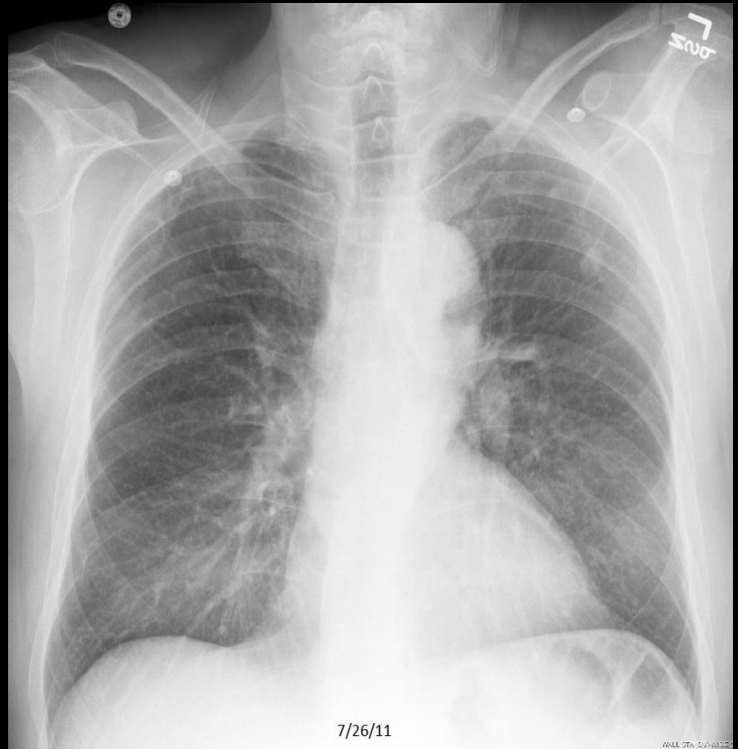
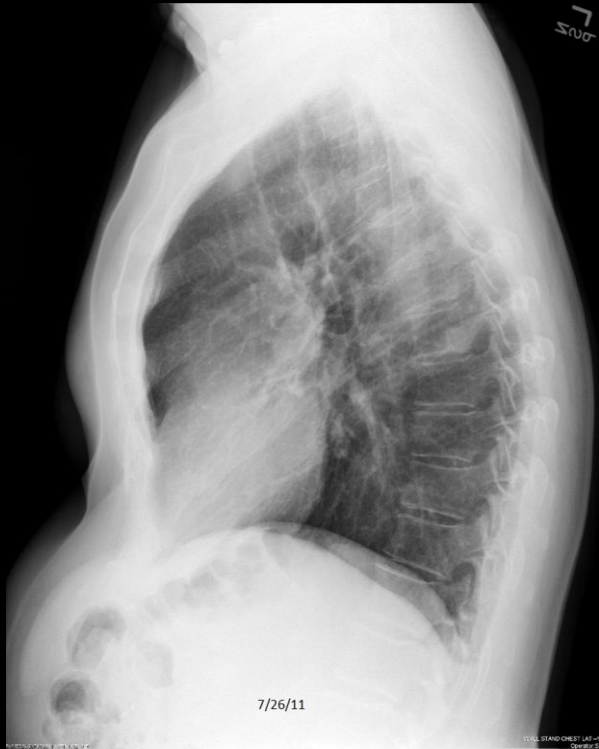

# QUIZ

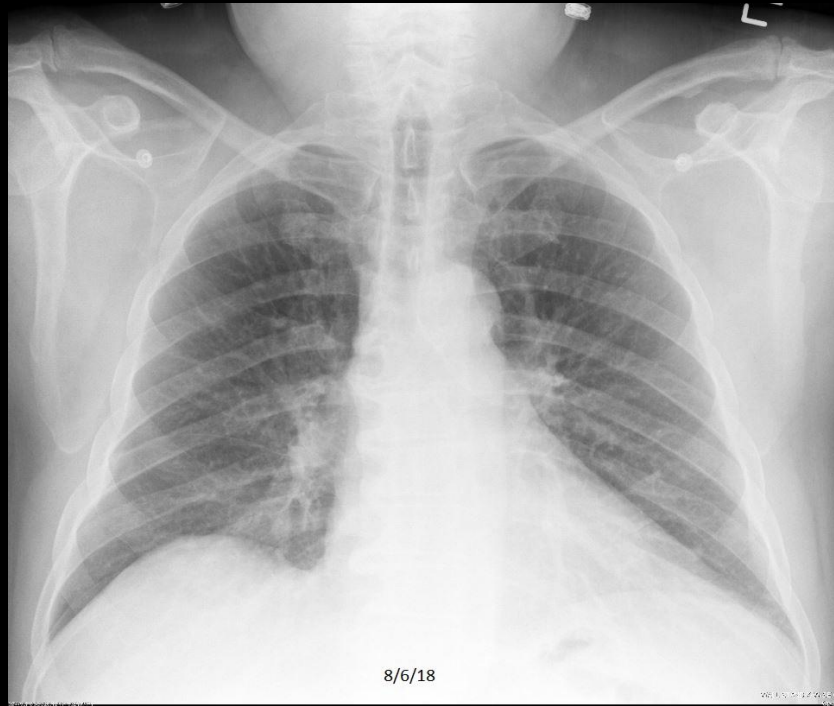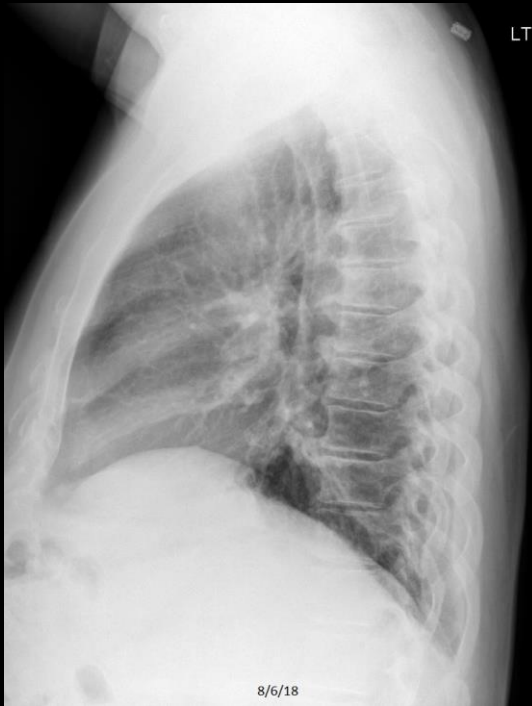## NORMAL VERSUS METASTATIC DISEASE

Select which CXR shows a Pulmonary Nodule  
(a or b)  
for the following 5 pairs of cases

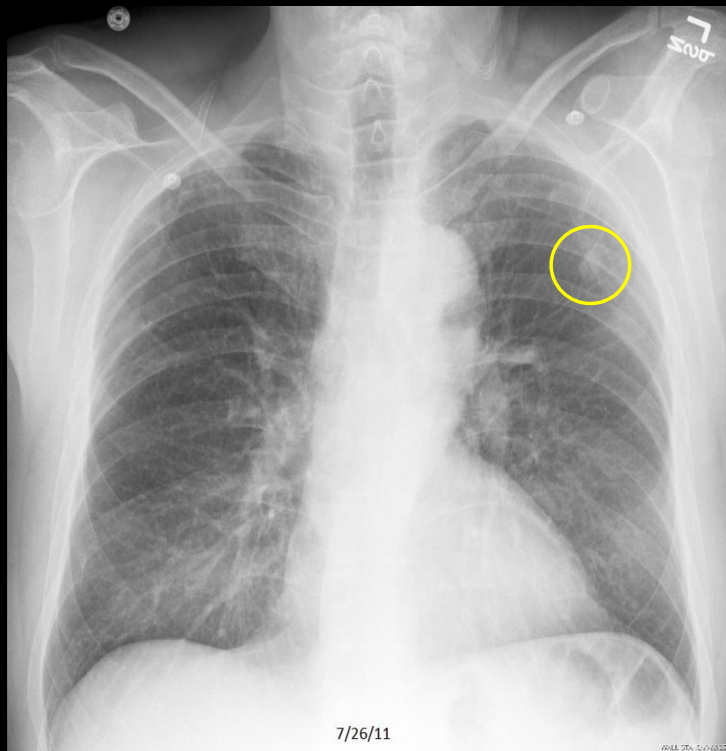
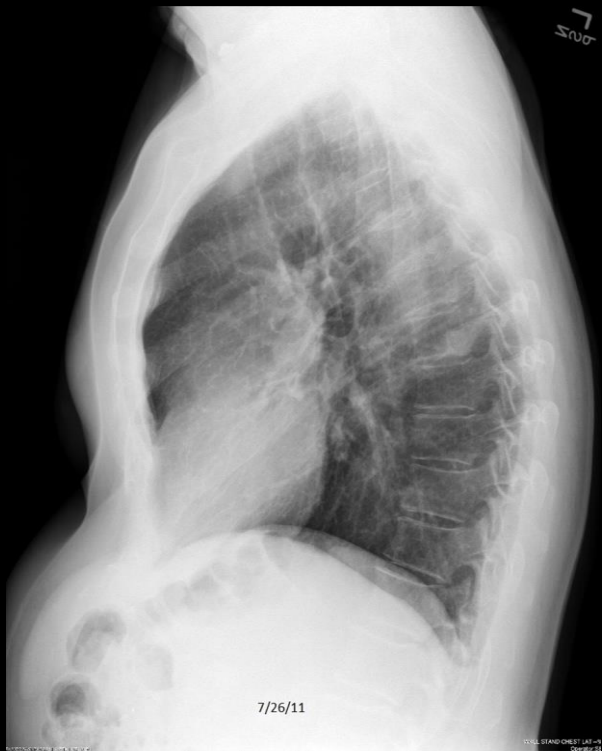## Quiz Case 1 of 5 - A



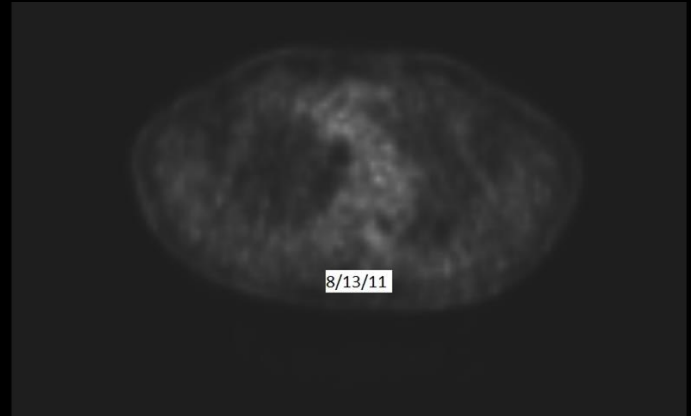
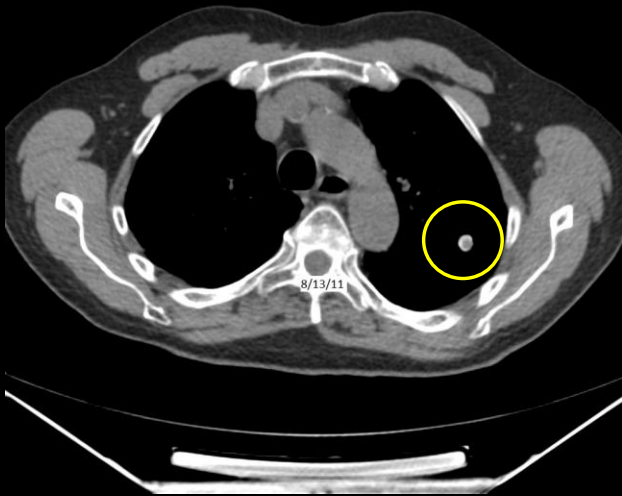
## Quiz Case 1 of 5 - B



# Quiz Case 1 of 5 – A shows a Pulmonary Nodule



# Quiz Case 1 of 5 – A shows a Pulmonary Nodule

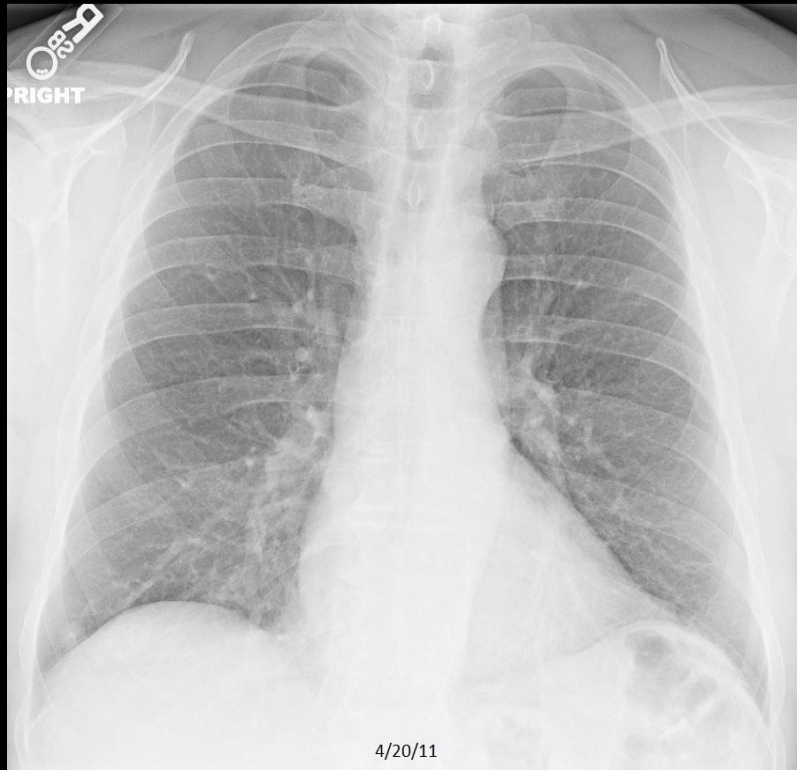
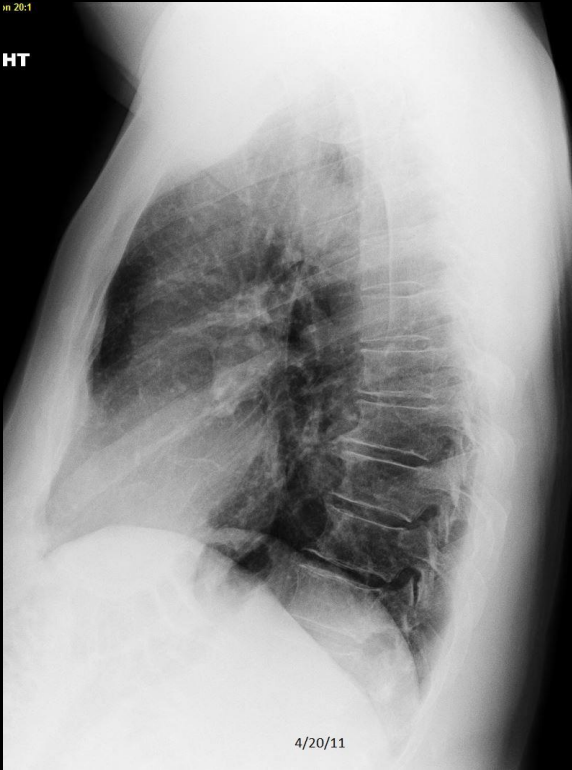

C506. 83 year old with pleuritic chest pain. Left pulmonary nodule. PET/CT study shows a calcified and nonhypermetabolic lesion, in keeping with a benign granuloma.

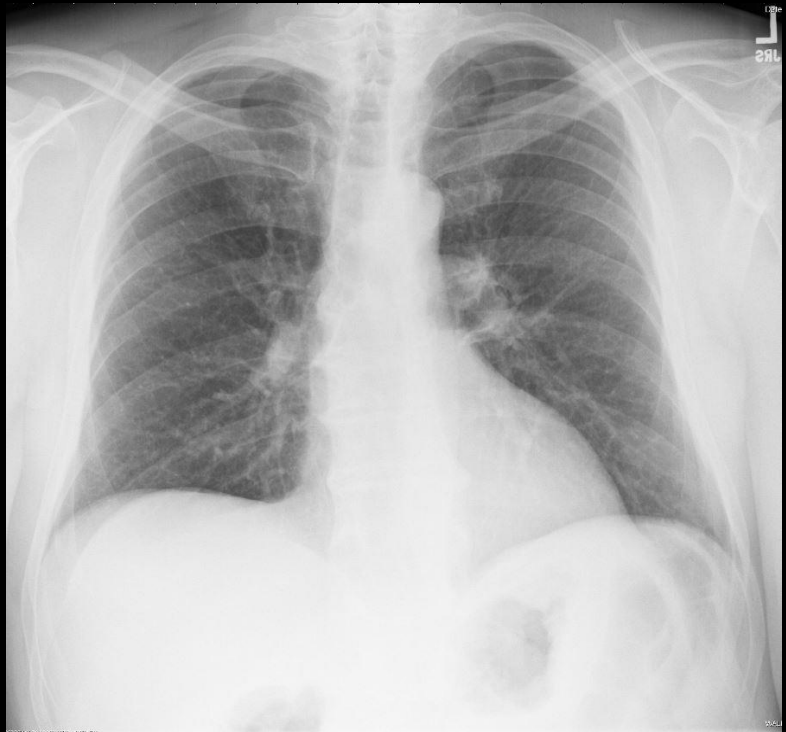
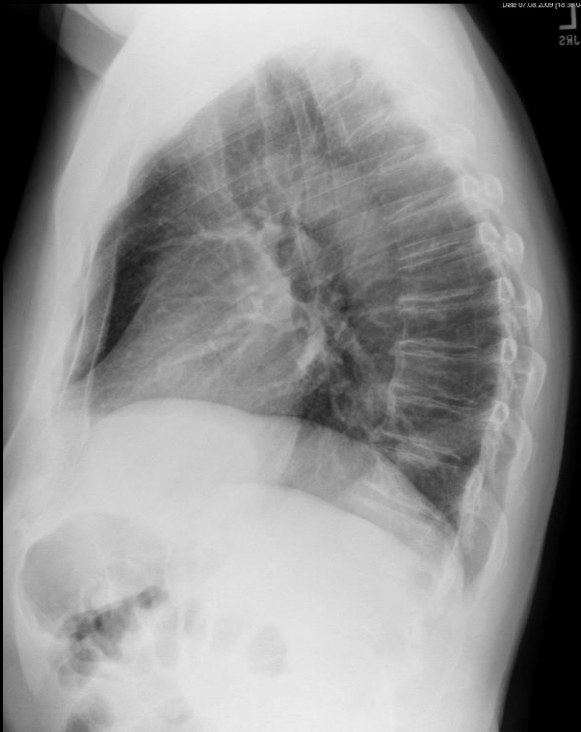## Quiz Case 2 of 5 - A

in 20:1

HT



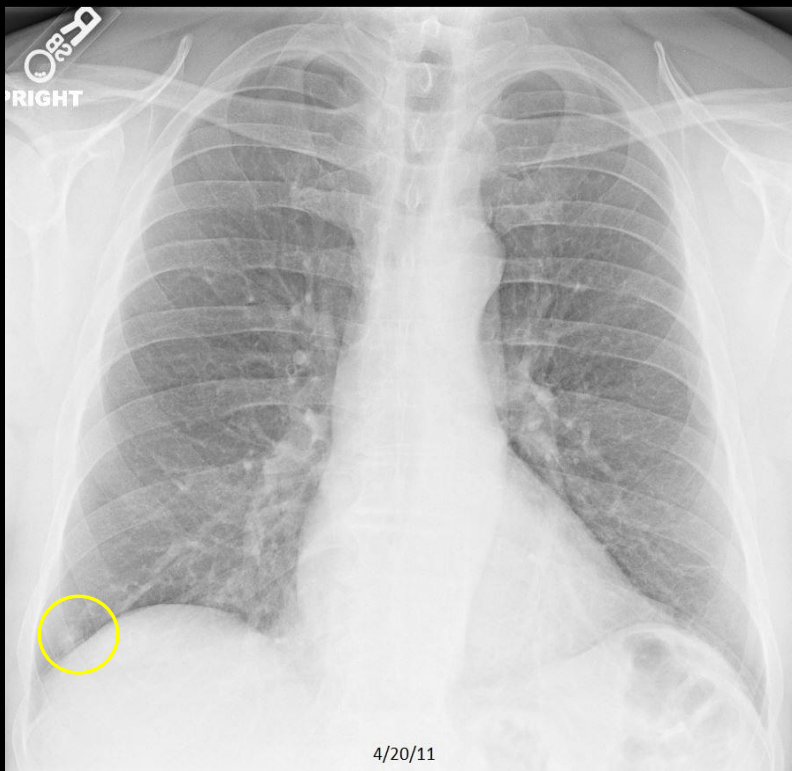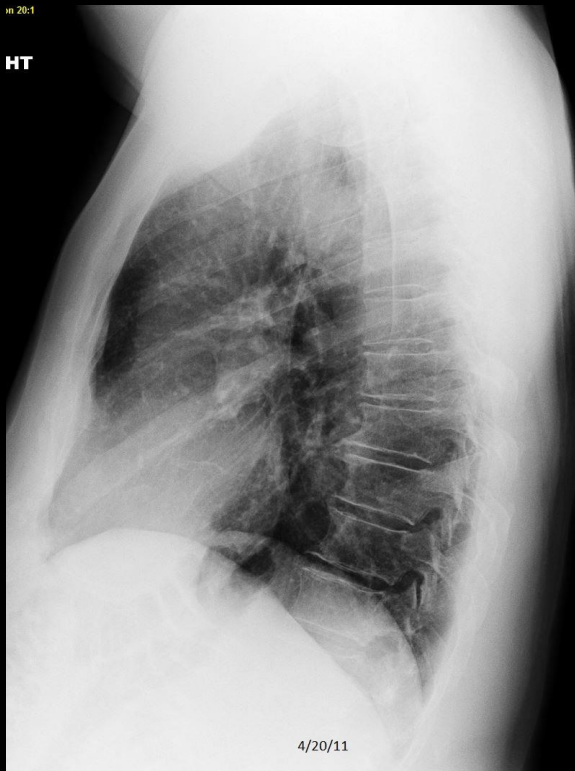## Quiz Case 2 of 5 - B



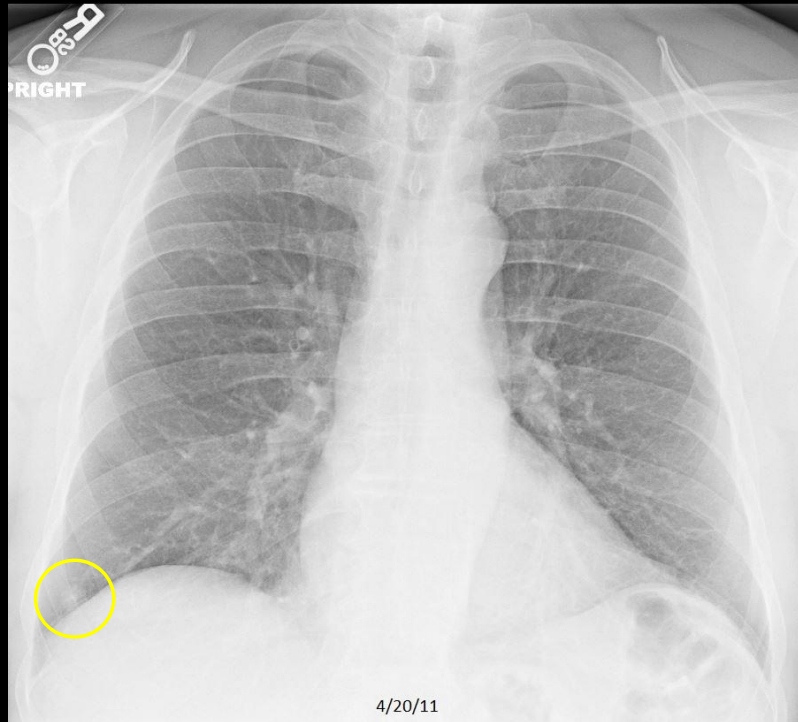
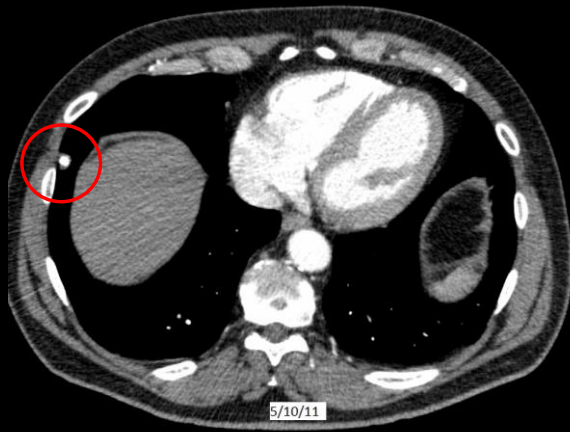
## Quiz Case 2 of 5 – A shows a Pulmonary Nodule

in 20:1

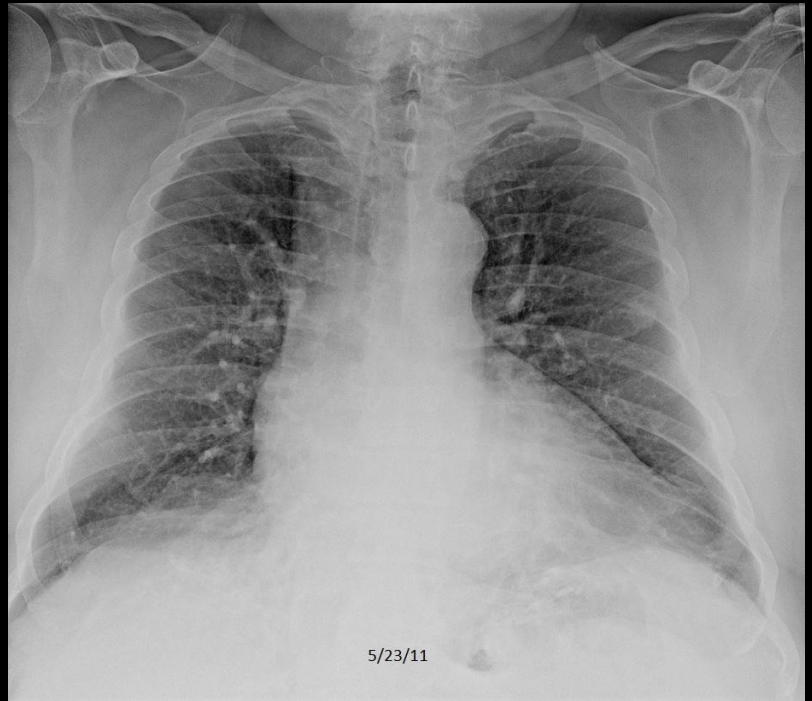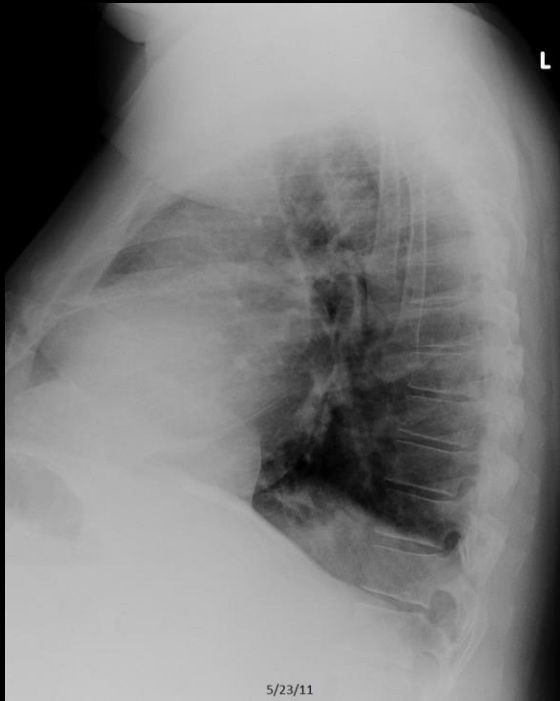HT



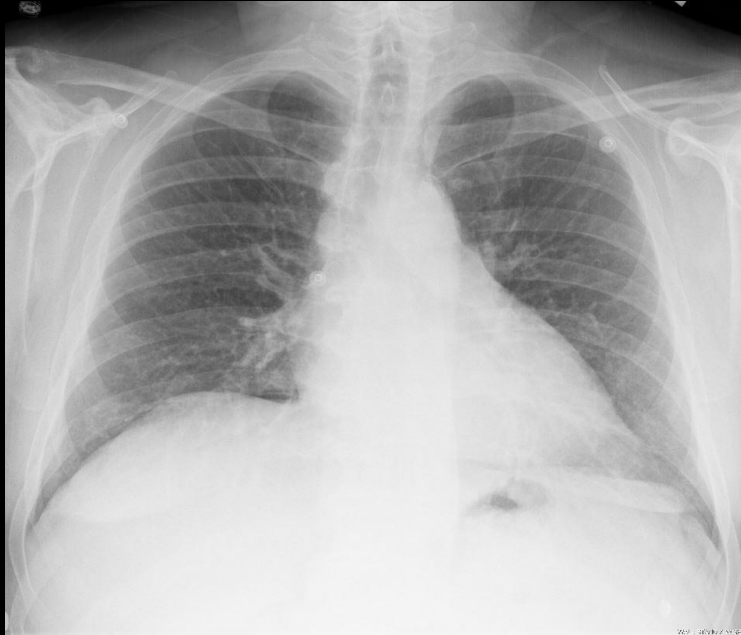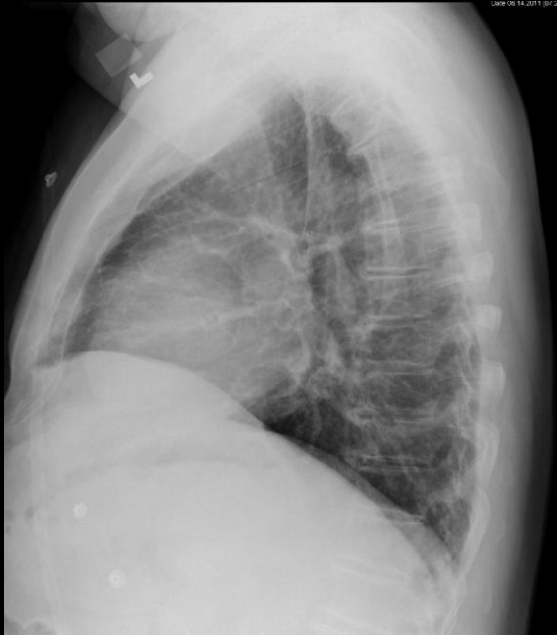## Quiz Case 2 of 5 – A shows a Pulmonary Nodule



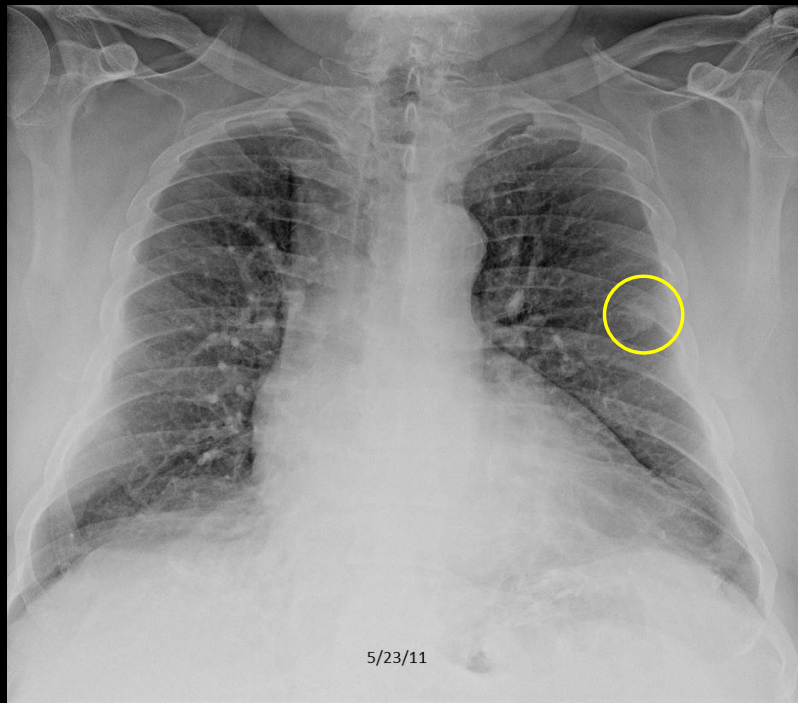
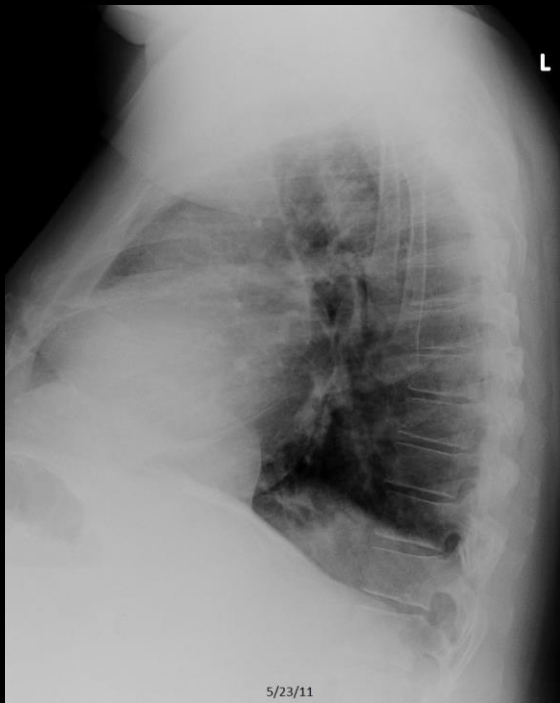## Quiz Case 3 of 5 - A



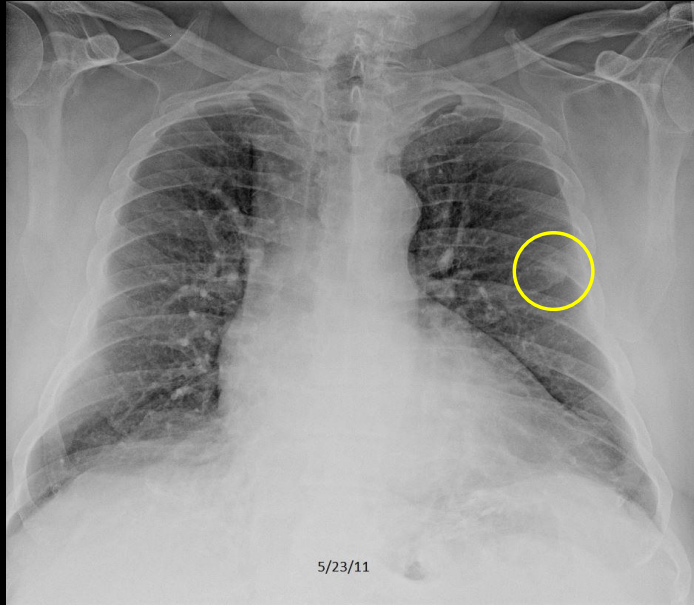
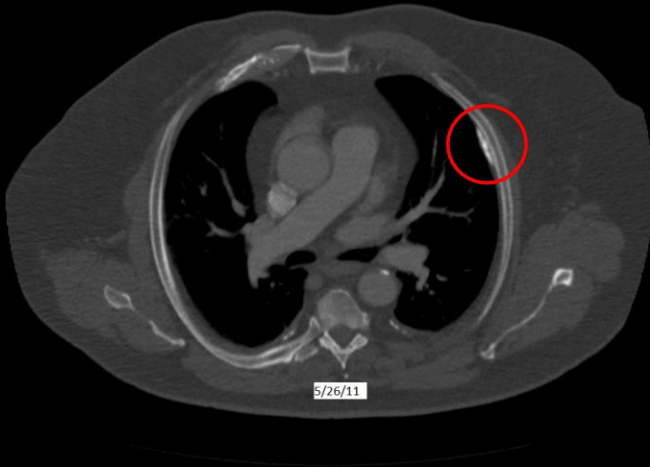
## Quiz Case 3 of 5 - B



## Quiz Case 3 of 5 – A shows a Pulmonary Nodule

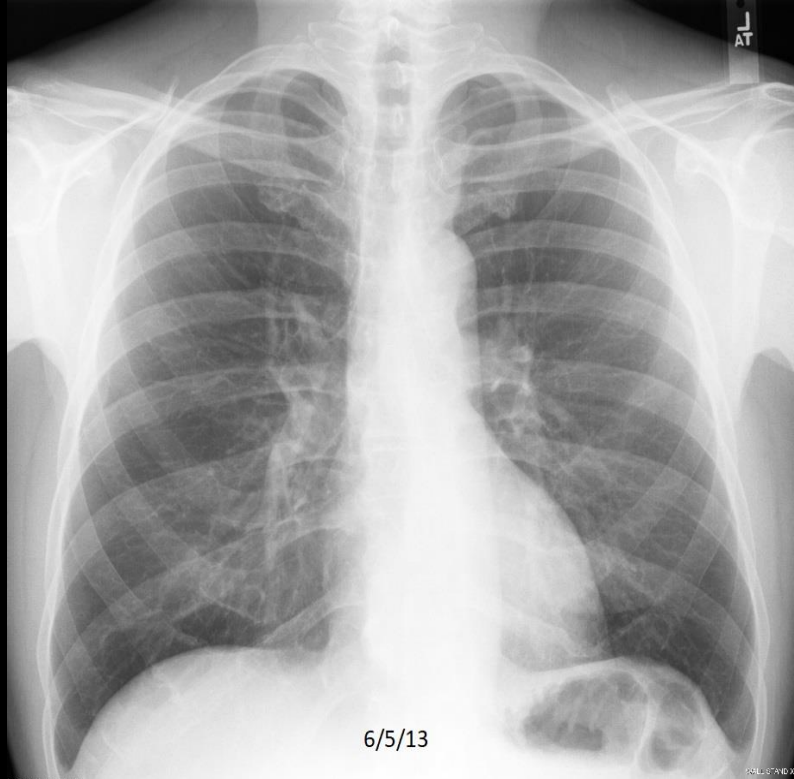
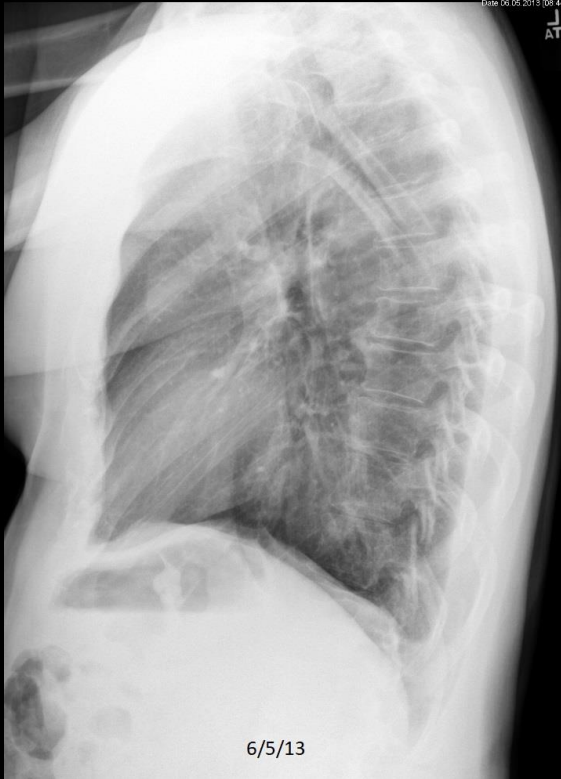

## Quiz Case 3 of 5 – A shows a Pulmonary Nodule

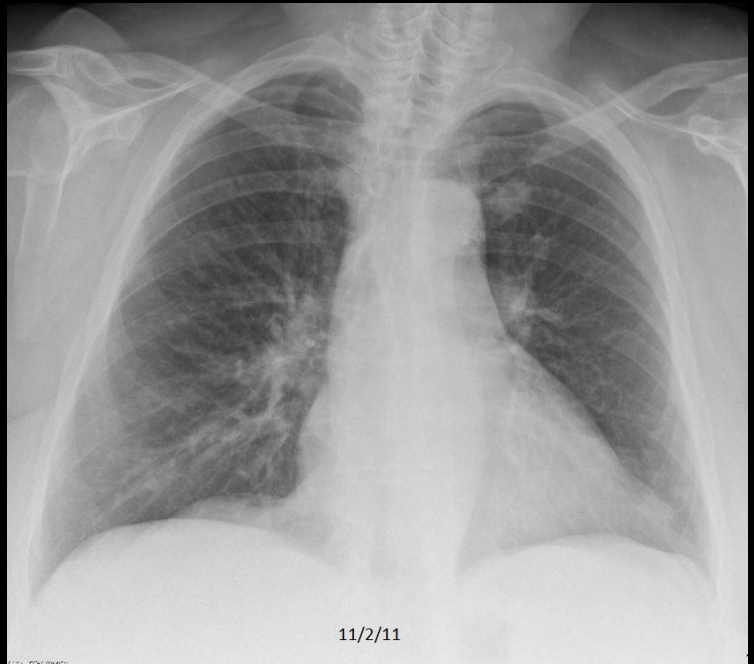
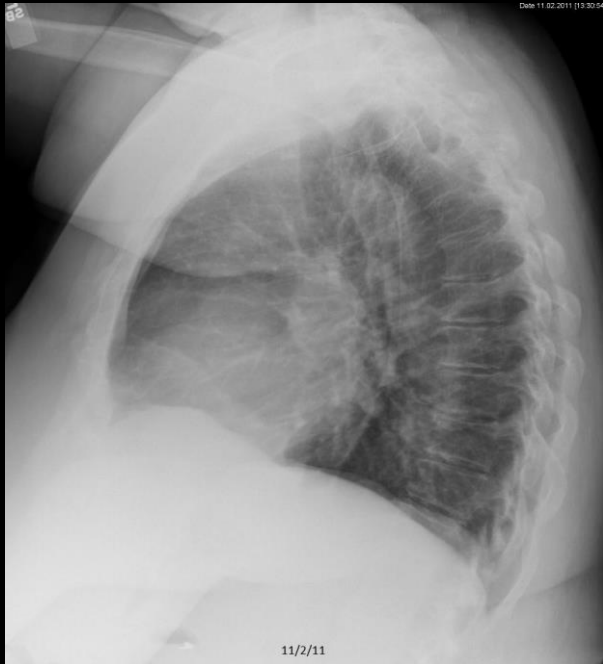

C508. 69 year old man with dyspnea. **Left pulmonary nodule**, which was new from a prior study (not shown). **Calcified pleural plaque on CT**.

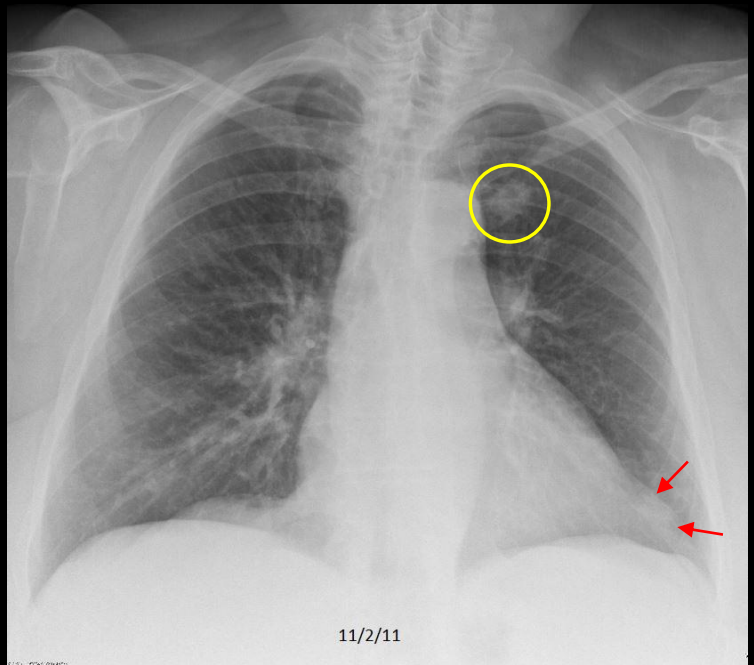
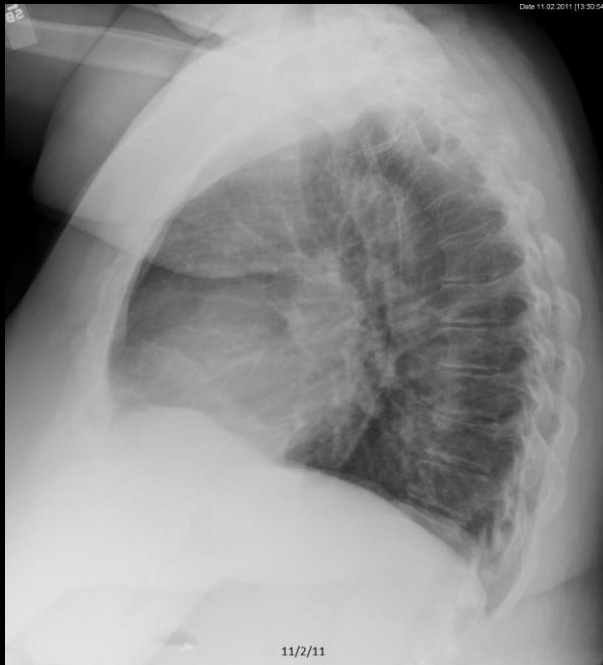## Quiz Case 4 of 5 - A



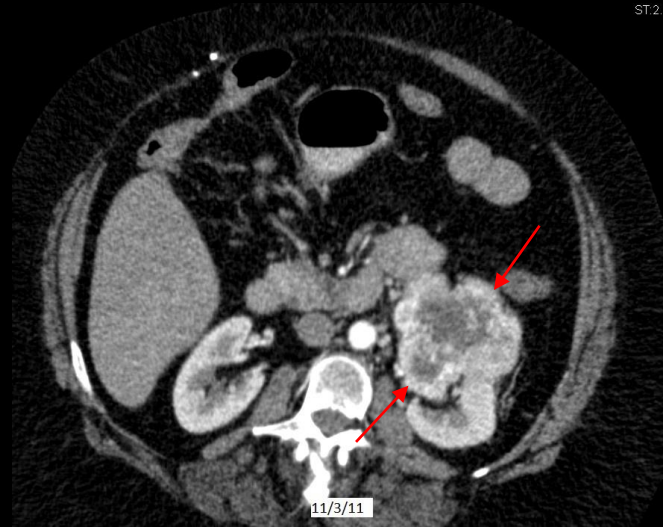
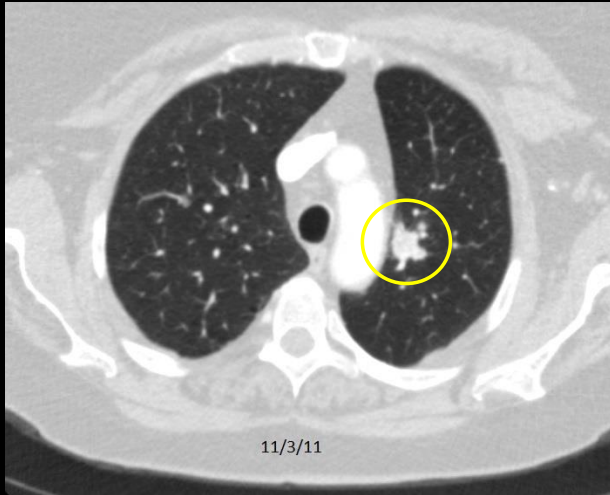
## Quiz Case 4 of 5 – B



## Quiz Case 4 of 5 - B shows a Pulmonary Nodule

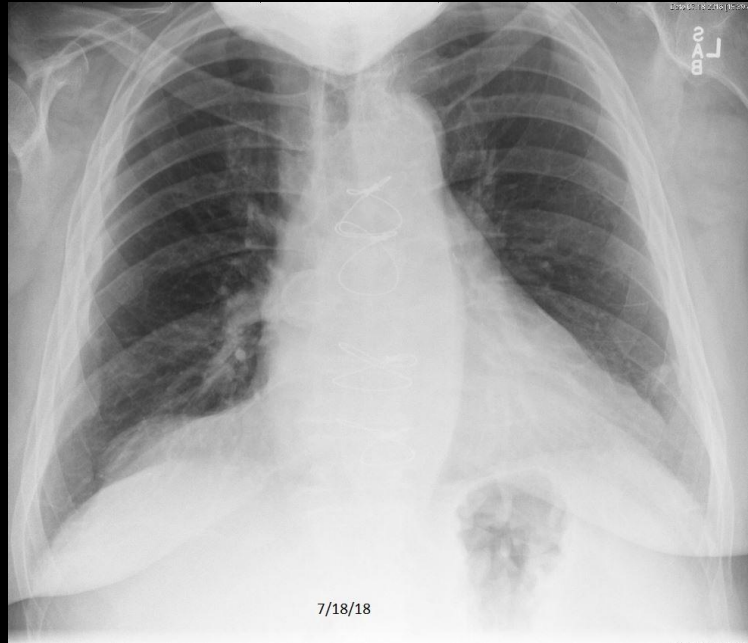
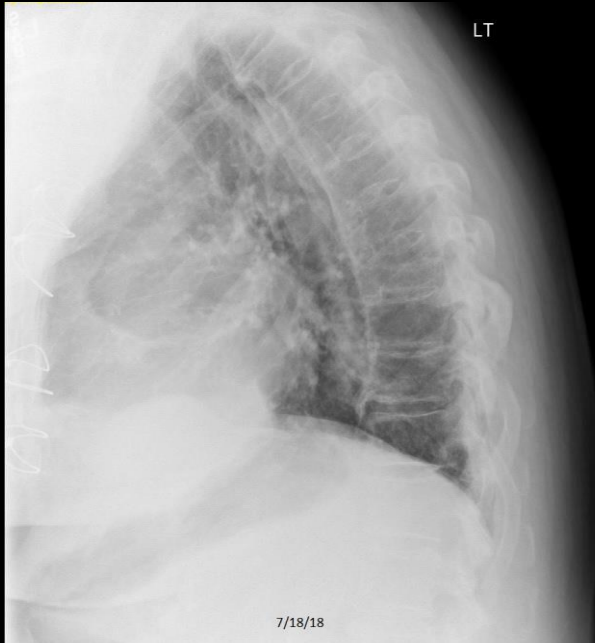

## Quiz Case 4 of 5 - B shows a Pulmonary Nodule

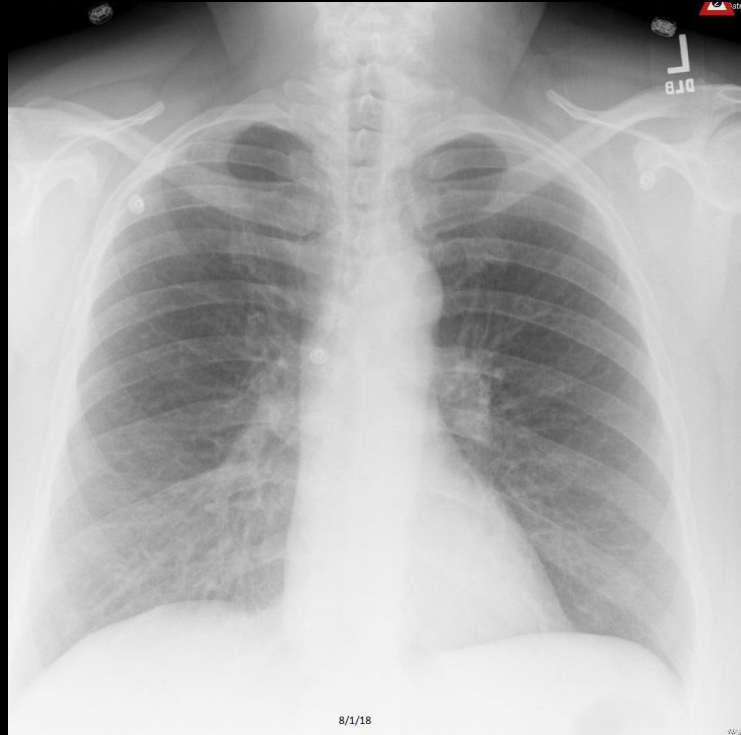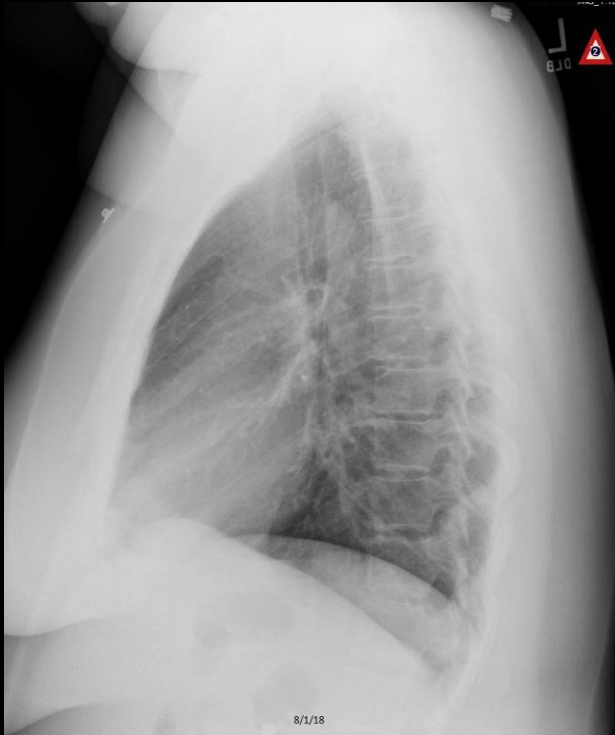


C510. 59 year old man with dyspnea. **Left pulmonary nodule.** Additional chest nodules (not shown) along with a **primary renal cell cancer.**

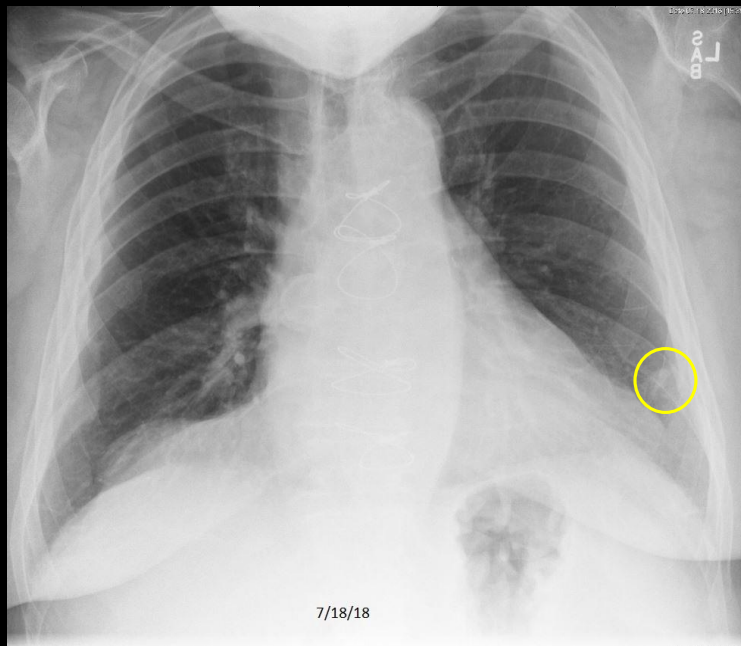
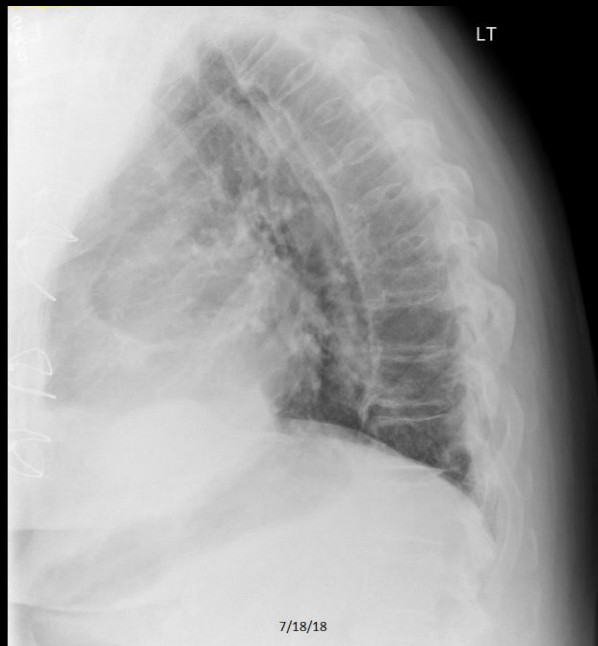
## Quiz Case 5 of 5 - A



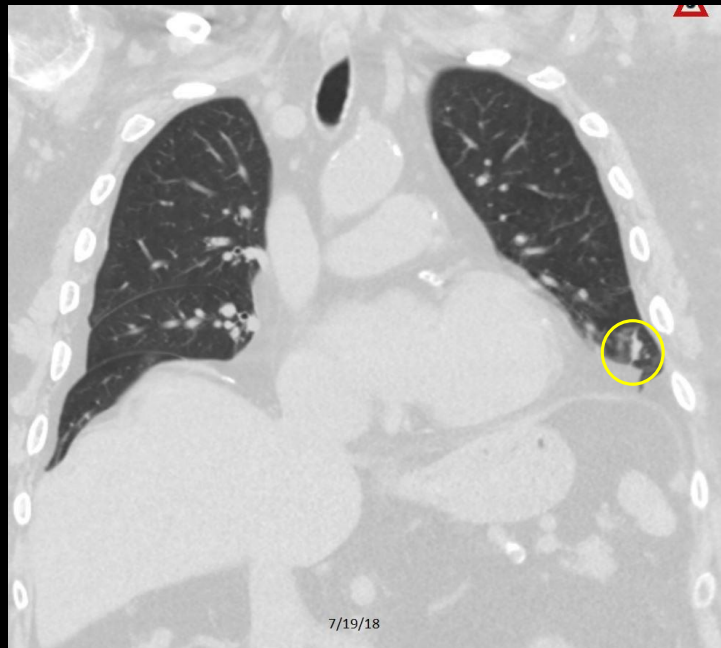
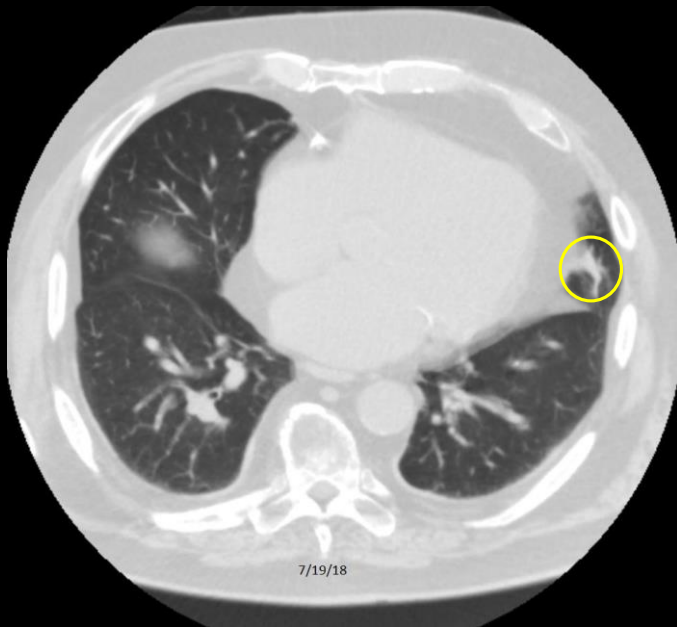
## Quiz Case 5 of 5 - B



# Quiz Case 5 of 5 – A shows a Pulmonary Nodule



## Quiz Case 5 of 5 – A shows a Pulmonary Nodule



C558. 81 year old man with dyspnea. **Left pulmonary nodule.** The lesion was not hypermetabolic on PET scan and was smaller on follow-up CT scan. Presumed scar/atelectasis.

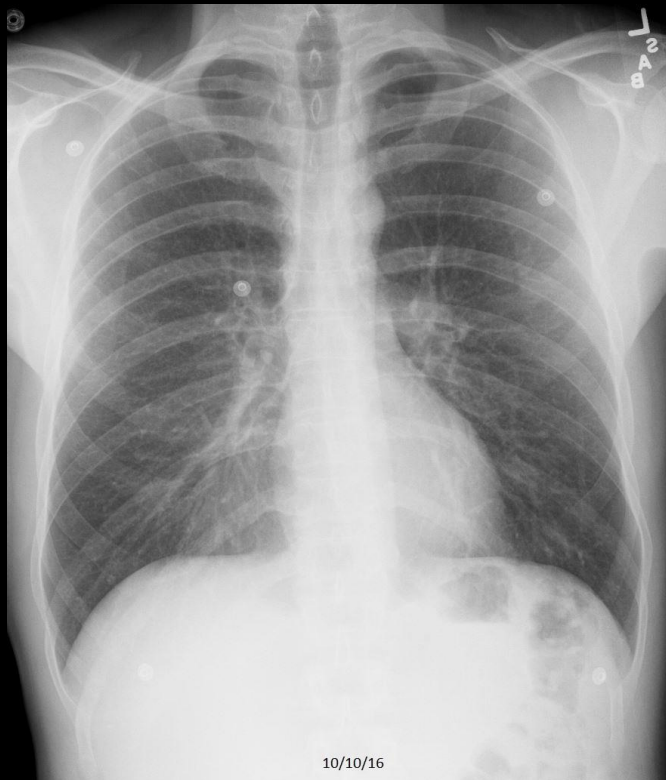
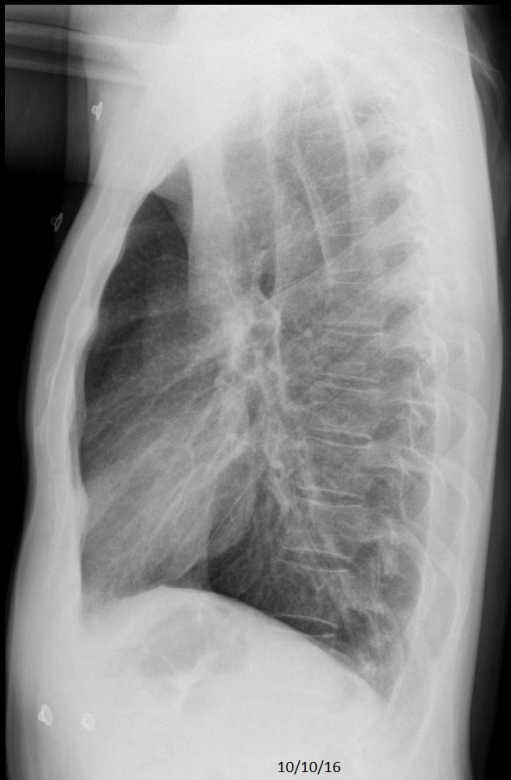# **Review Quiz**

**Identify Each CXR as:**

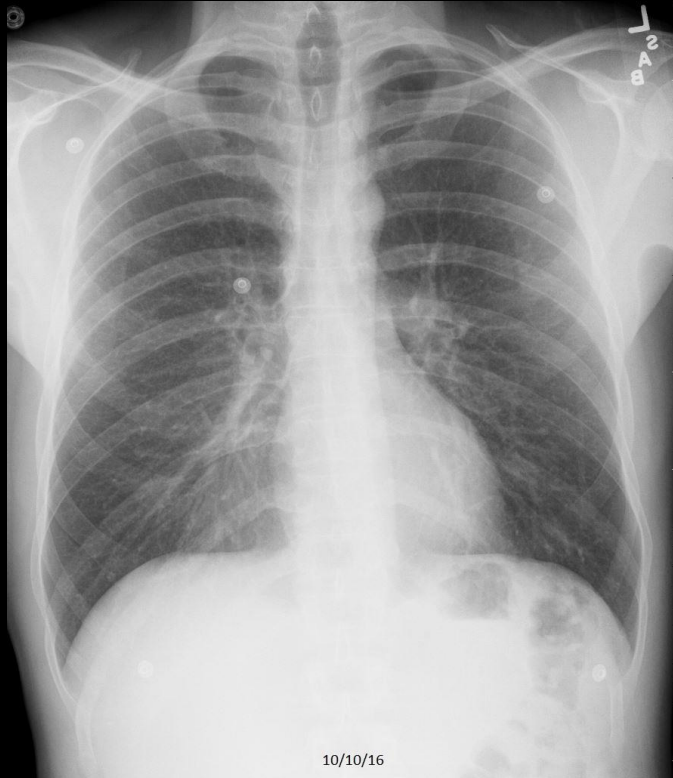
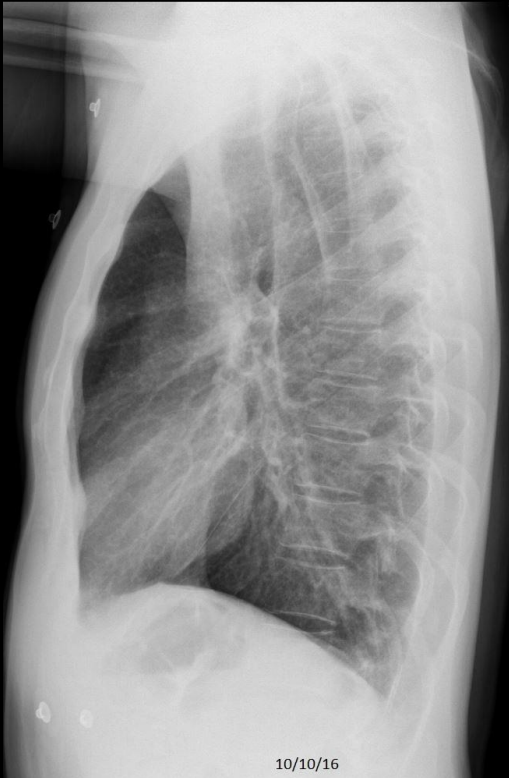**Normal, CHF, Pneumonia, Emphysema,  
Cardiomegaly without CHF, Atelectasis/Scar,  
Focal Chest Density, Pleural Effusion, Hiatal  
Hernia, Fracture, Diffuse Lung Density,  
Calcified Pleural Plaque, Free Air, Calcified  
Granuloma, Metastatic Disease, or Pulmonary  
Nodule**

## Review Quiz Case 1 of 10

Normal, CHF, Pneumonia, Emphysema, Cardiomegaly without Failure, Atelectasis/Scar, Focal Chest Density, Pleural Effusion, Hiatal Hernia, Fracture, Diffuse Lung Density, Calcified Pleural Plaque, Free Air, Calcified Granuloma, Metastatic Disease, or Pulmonary Nodule

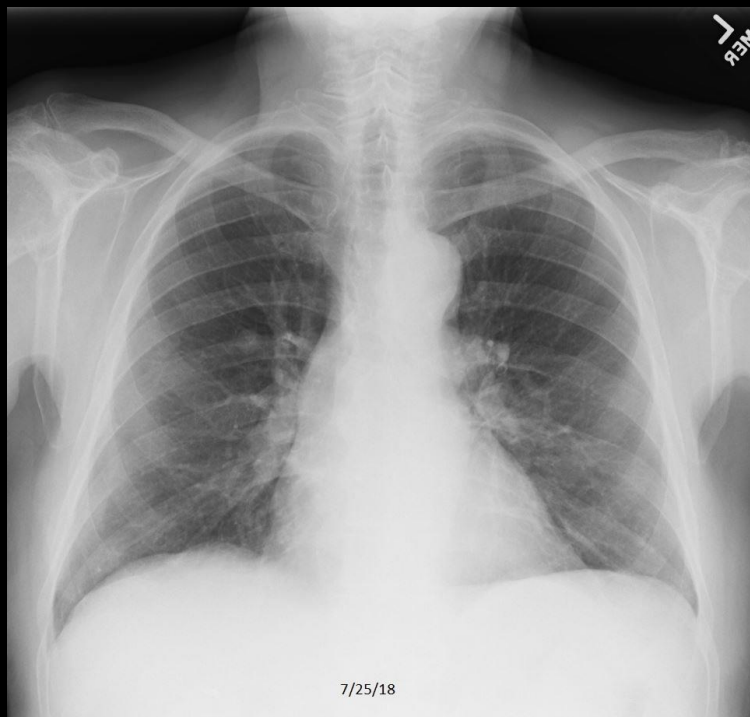
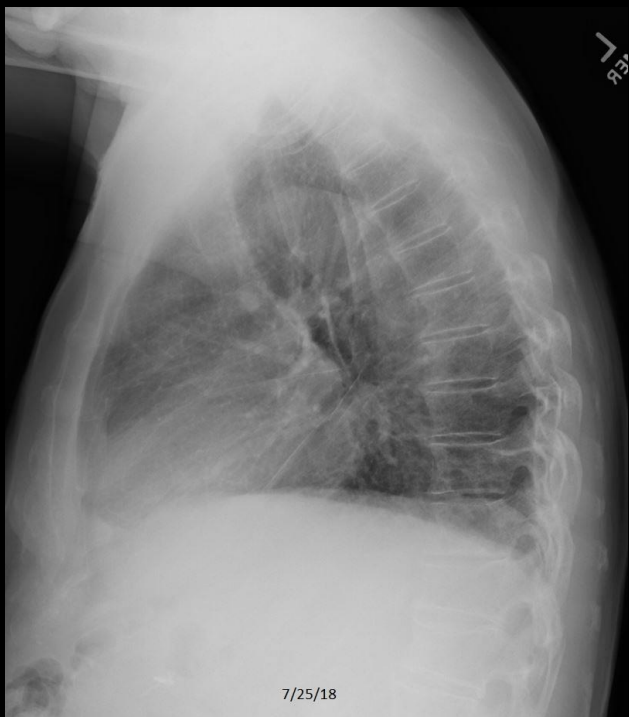

Review Quiz Case 1 of 10  
Normal

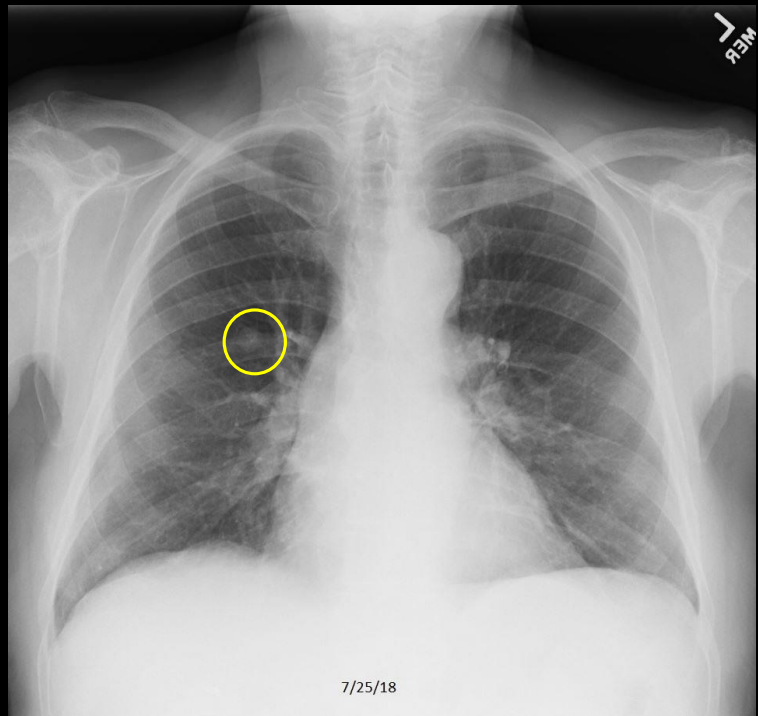
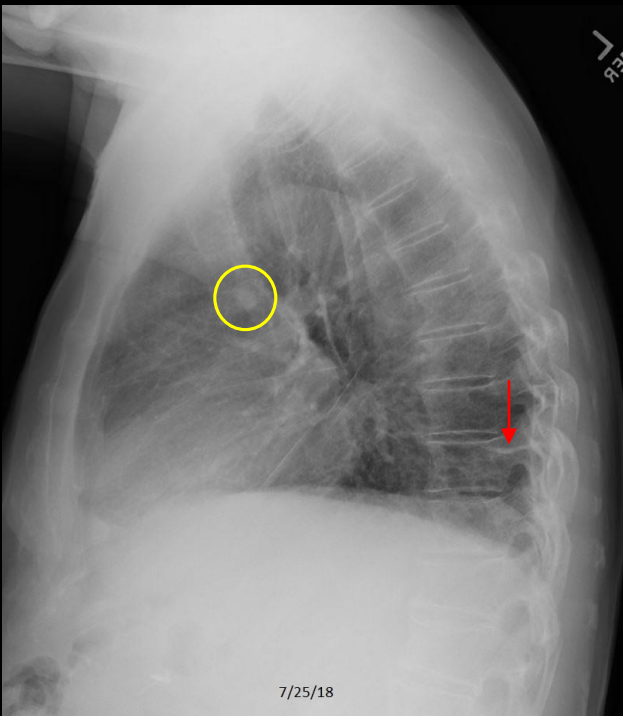


## Review Quiz Case 2 of 10

Normal, CHF, Pneumonia, Emphysema, Cardiomegaly without Failure, Atelectasis/Scar, Focal Chest Density, Pleural Effusion, Hiatal Hernia, Fracture, Diffuse Lung Density, Calcified Pleural Plaque, Free Air, Calcified Granuloma, Metastatic Disease, or Pulmonary Nodule

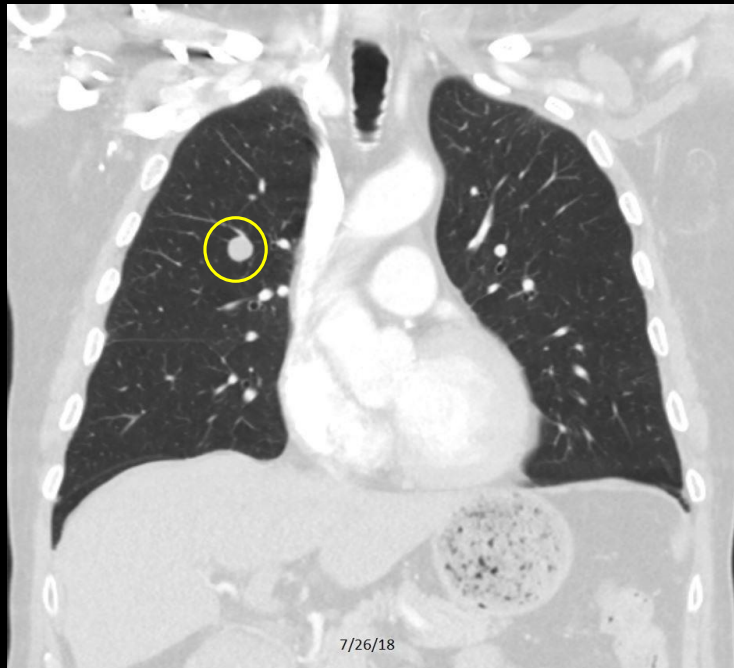
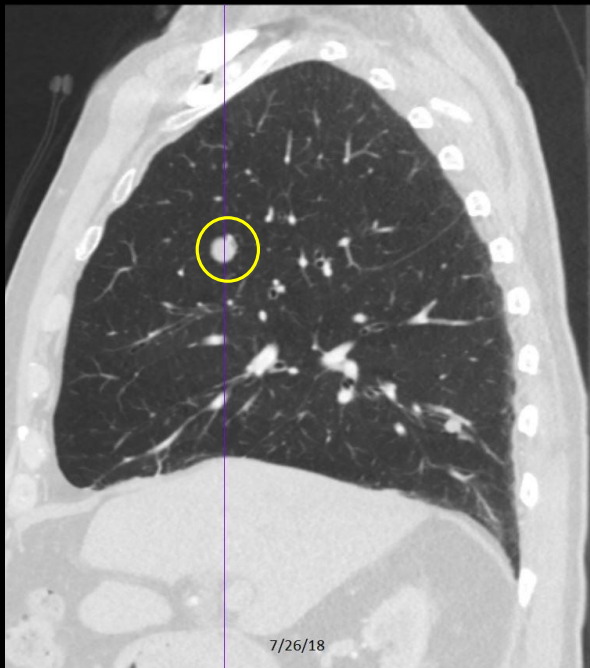


Review Quiz Case 2 of 10  
Atelectasis/Scar and Pulmonary Nodule



C559. 89 year old man with dyspnea. **Right pulmonary nodule.** **Atelectasis/scar** seen on the lateral exam.

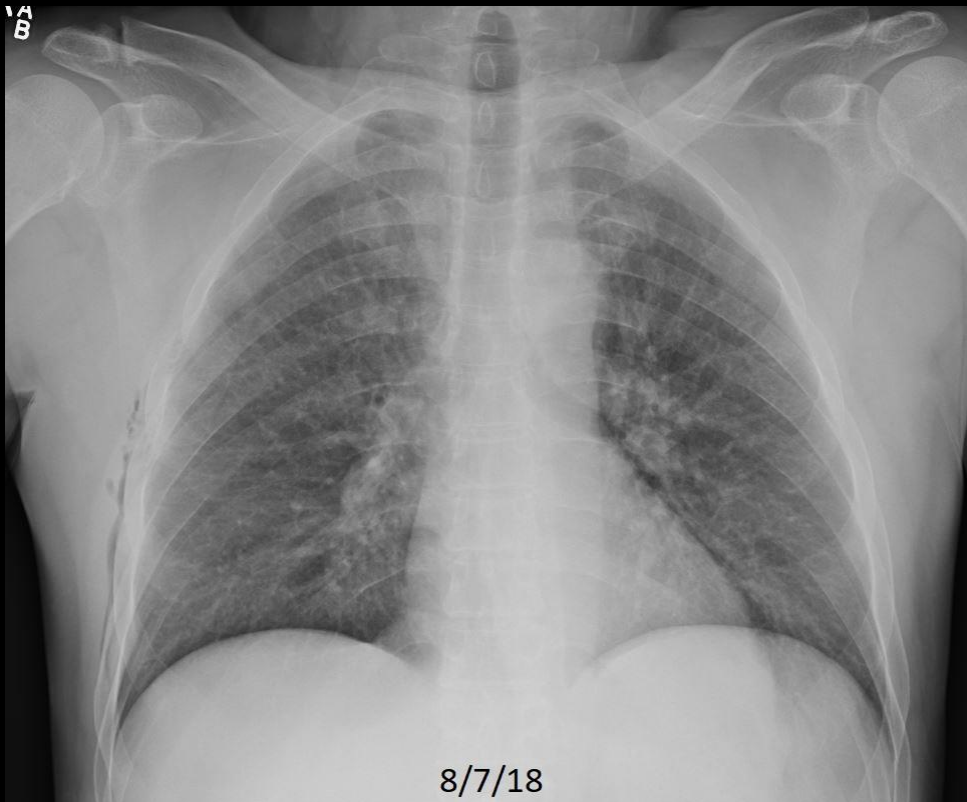
Review Quiz Case 2 of 10  
Atelectasis/Scar and Pulmonary Nodule



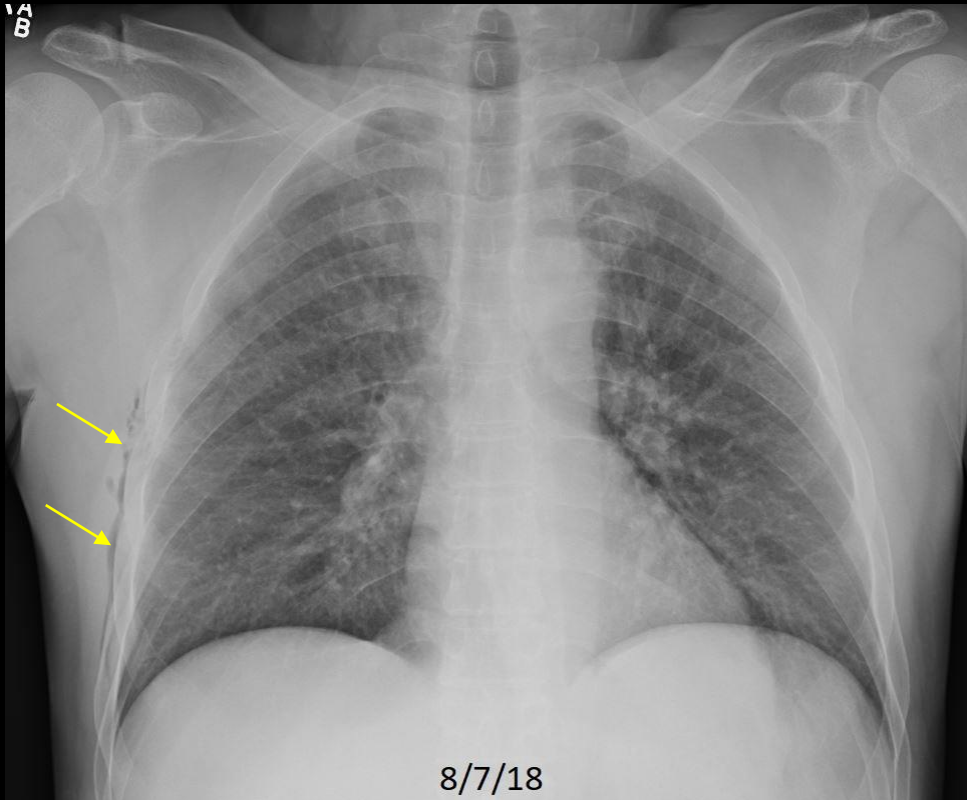
C559. 89 year old man with dyspnea. **Right pulmonary nodule.** Nonhypermetabolic on PET study. Unchanged on follow-up in keeping with a benign granuloma.

### Review Quiz Case 3 of 10

Normal, CHF, Pneumonia, Emphysema, Cardiomegaly without Failure, Atelectasis/Scar, Focal Chest Density, Pleural Effusion, Hiatal Hernia, Fracture, Diffuse Lung Density, Calcified Pleural Plaque, Free Air, Calcified Granuloma, Metastatic Disease, or Pulmonary Nodule

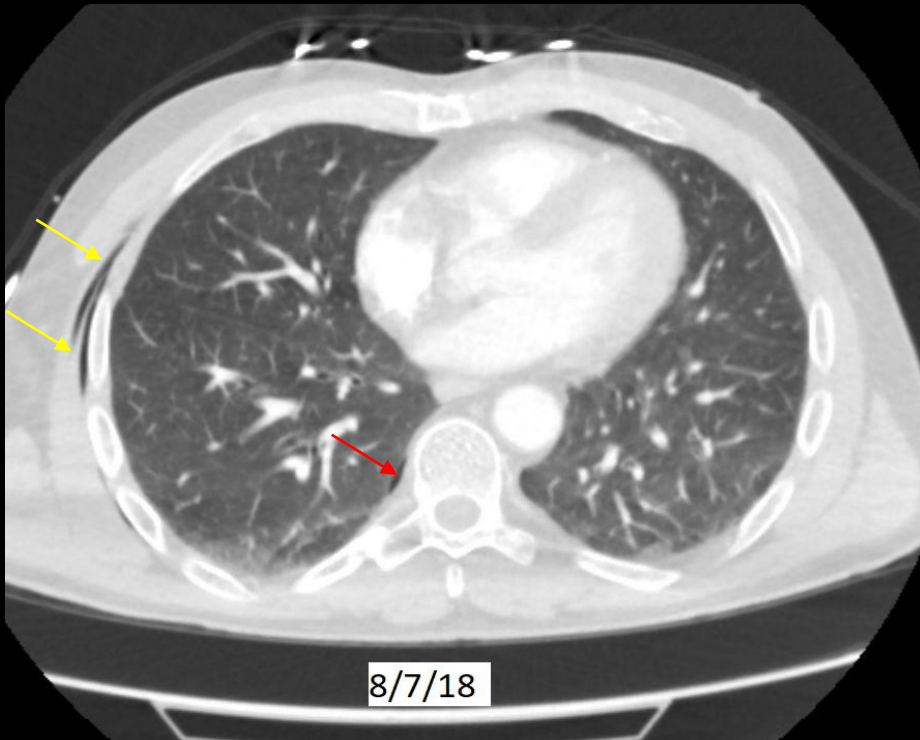


Review Quiz Case 3 of 10  
Free Air



C580. 50 year old with chest pain following injury. **Chest wall emphysema.**

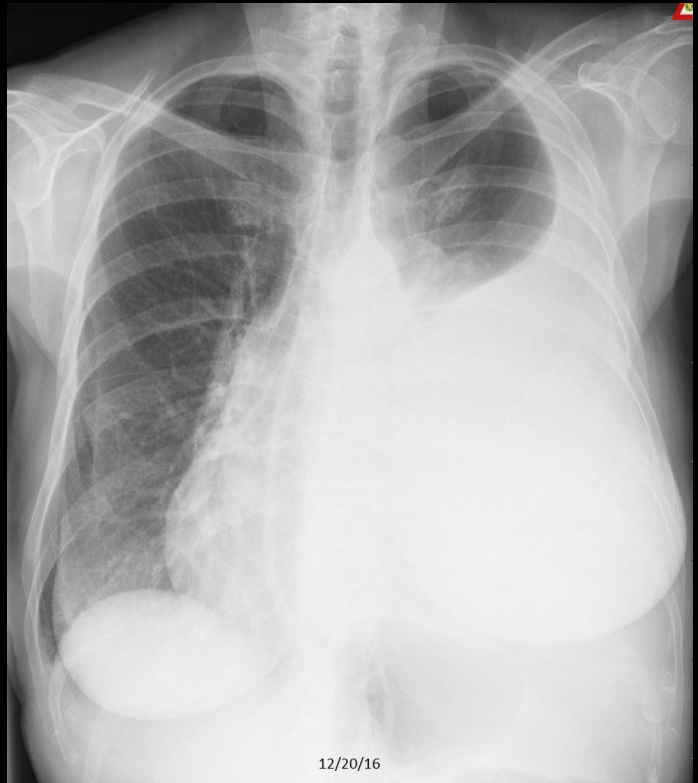
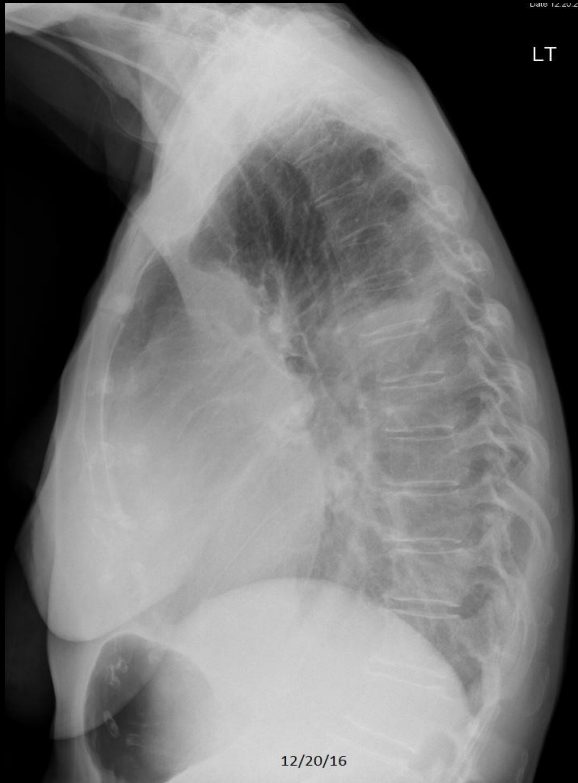Review Quiz Case 3 of 10  
Free Air



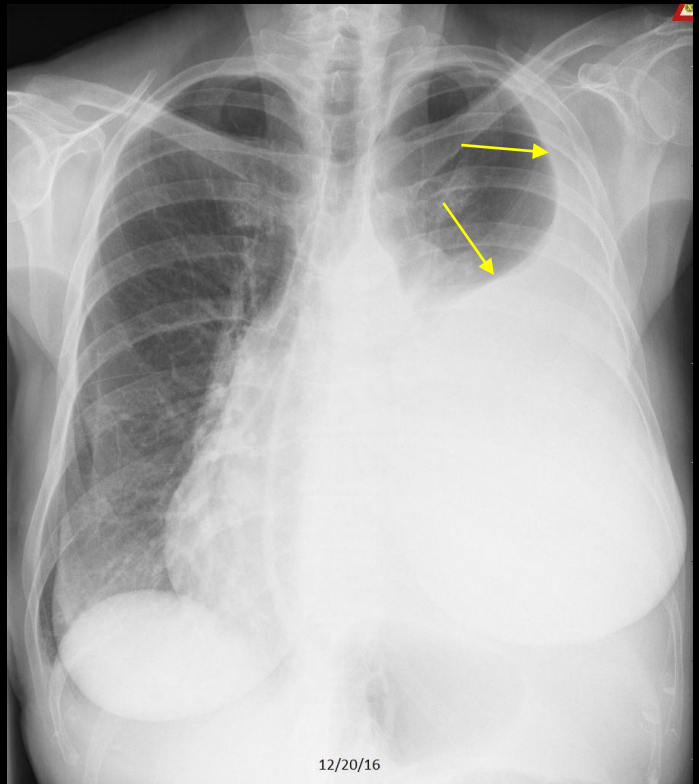
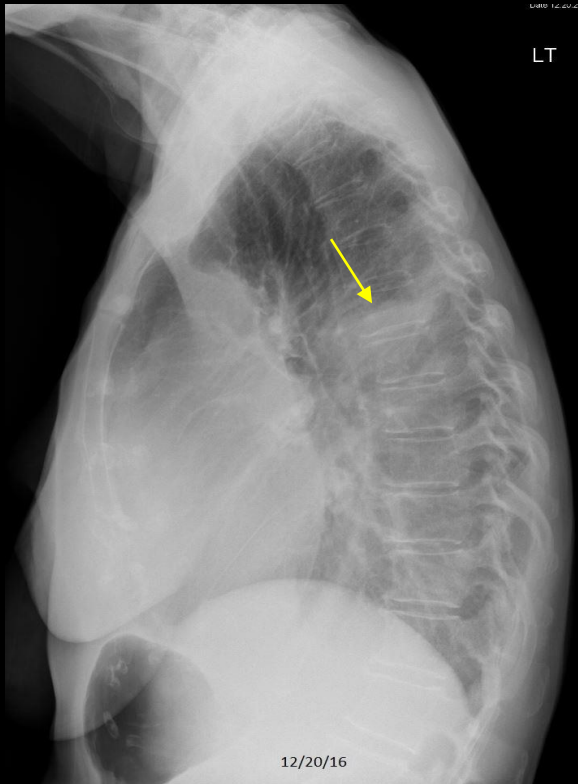
C580. 50 year old with chest pain following injury. **Chest wall emphysema**. **Tiny amount of air along the pleural space** of the medial right lung. The patient had no obvious displaced rib fractures.

## Review Quiz Case 4 of 10

Normal, CHF, Pneumonia, Emphysema, Cardiomegaly without Failure, Atelectasis/Scar, Focal Chest Density, Pleural Effusion, Hiatal Hernia, Fracture, Diffuse Lung Density, Calcified Pleural Plaque, Free Air, Calcified Granuloma, Metastatic Disease, or Pulmonary Nodule

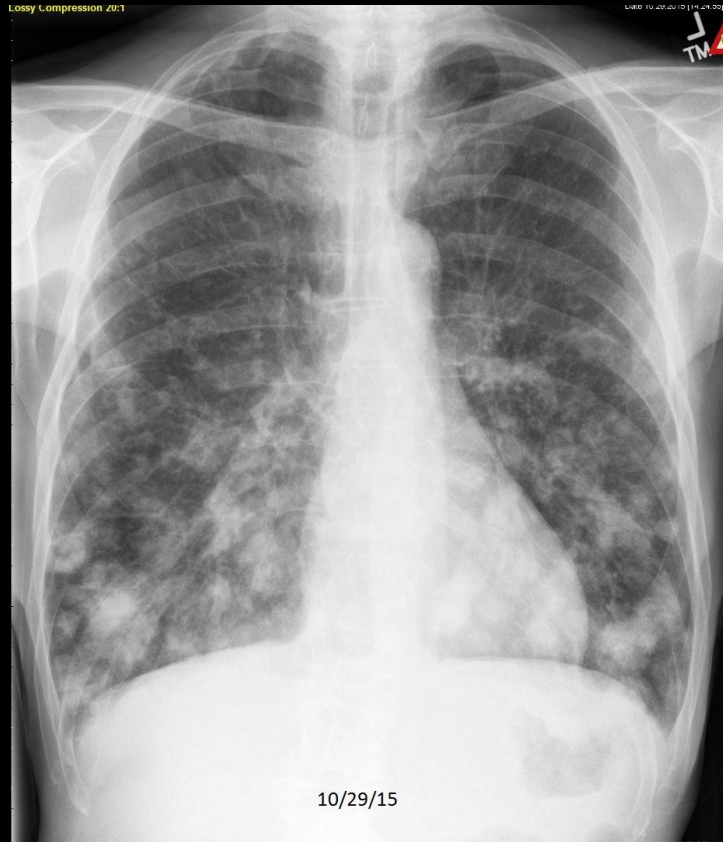
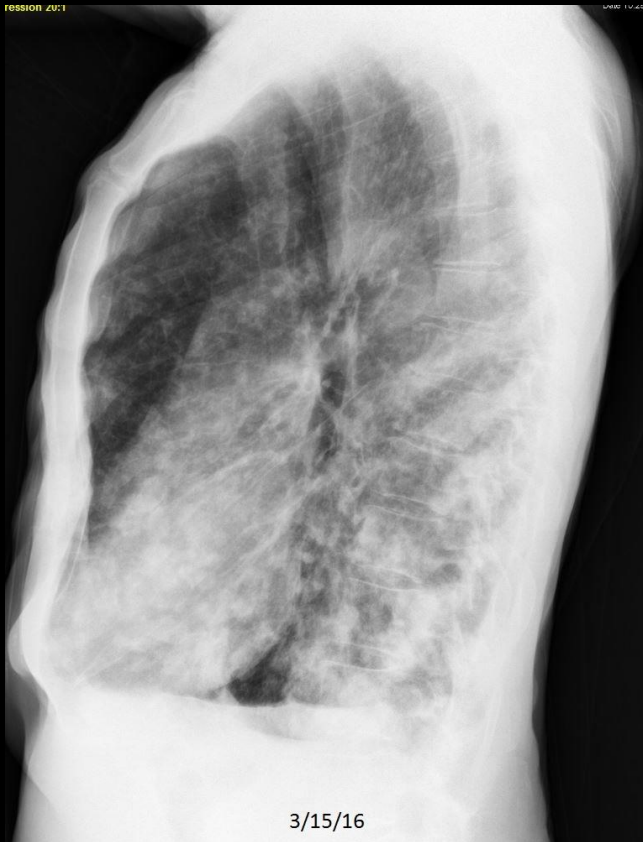
Review Quiz Case 4 of 10  
Pleural Effusion

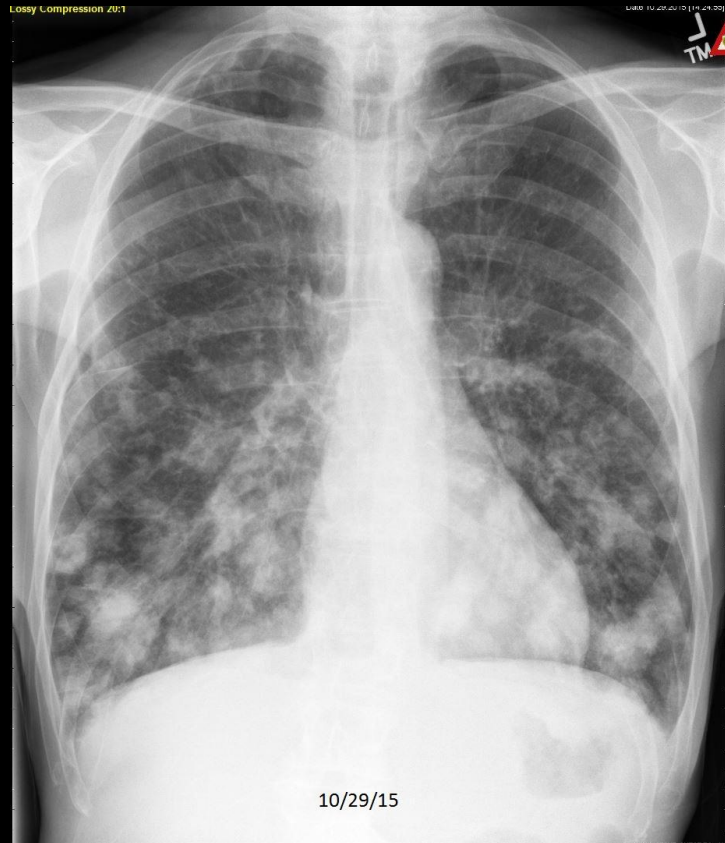
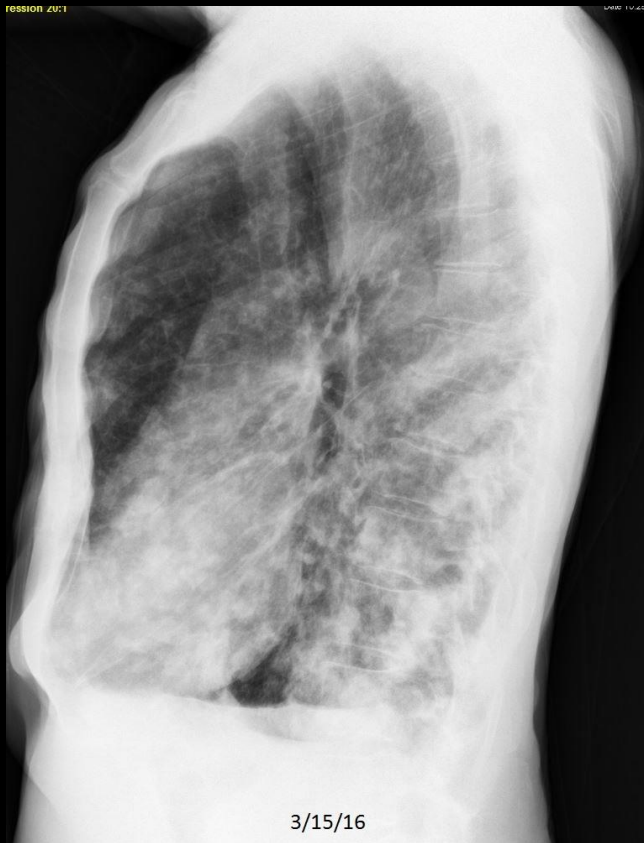
## Review Quiz Case 5 of 10

Normal, CHF, Pneumonia, Emphysema, Cardiomegaly without Failure, Atelectasis/Scar, Focal Chest Density, Pleural Effusion, Hiatal Hernia, Fracture, Diffuse Lung Density, Calcified Pleural Plaque, Free Air, Calcified Granuloma, Metastatic Disease, or Pulmonary Nodule

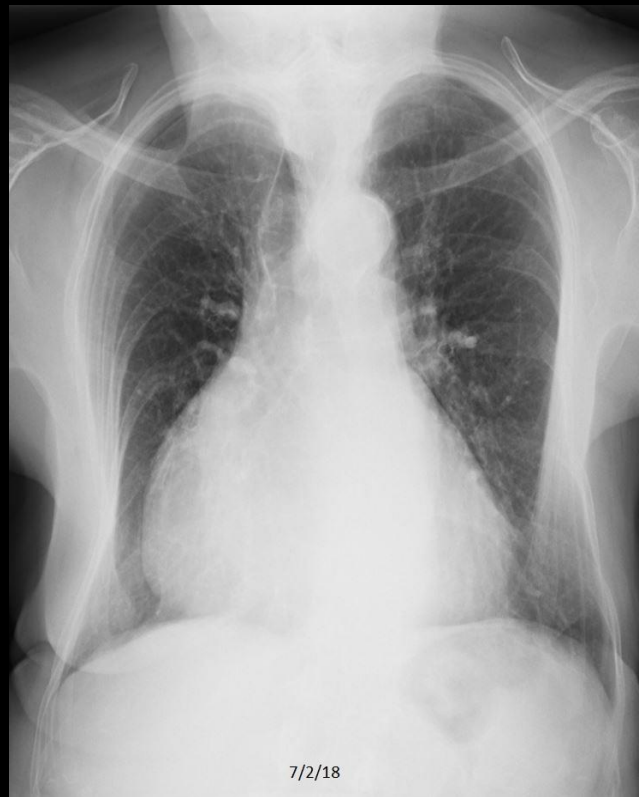
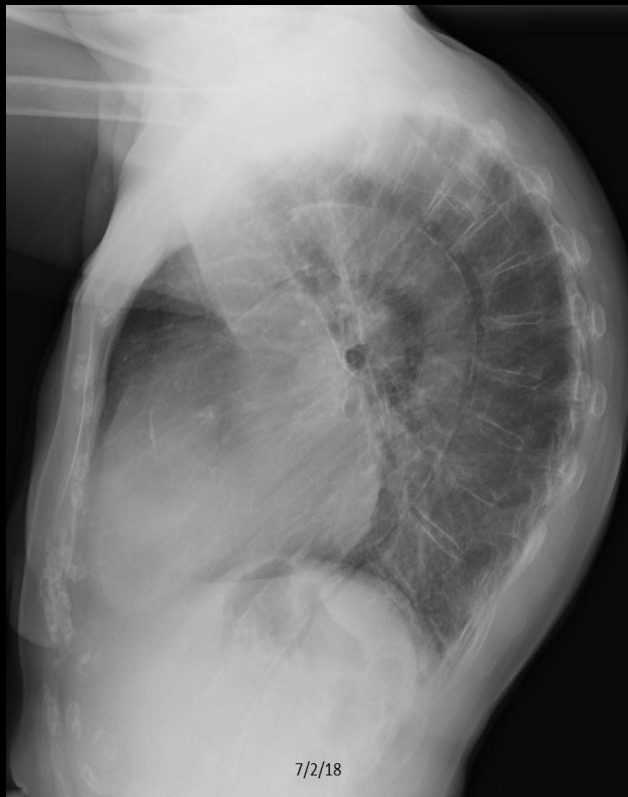
Review Quiz Case 5 of 10  
Metastatic Disease

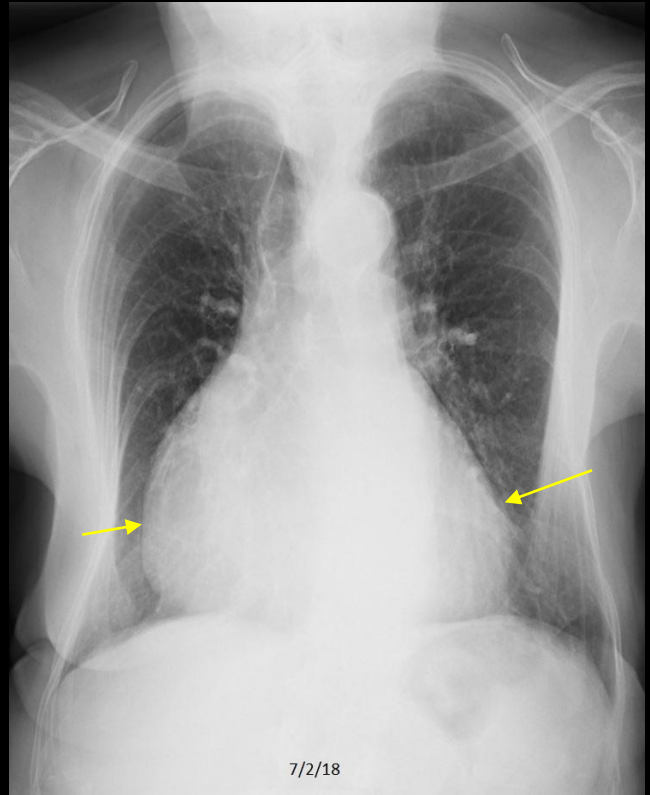
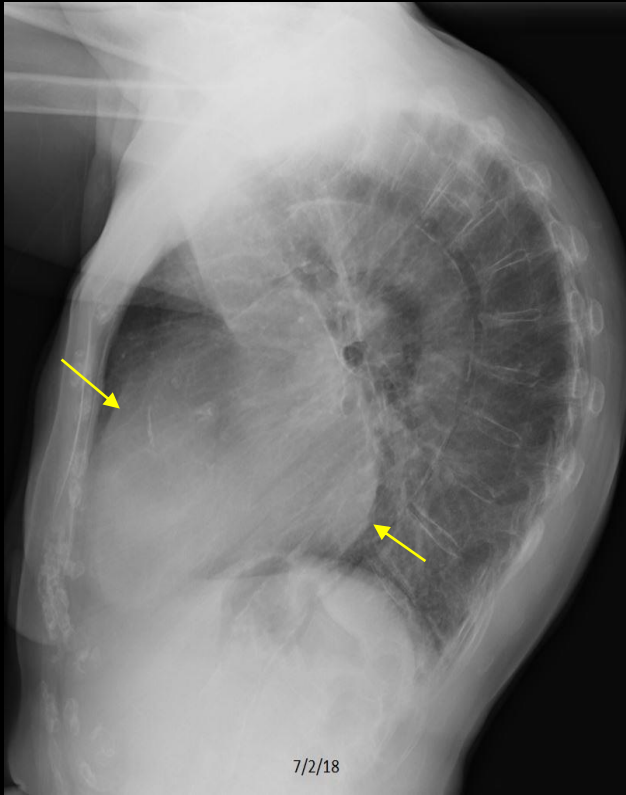


### Review Quiz Case 6 of 10

Normal, CHF, Pneumonia, Emphysema, Cardiomegaly without Failure, Atelectasis/Scar, Focal Chest Density, Pleural Effusion, Hiatal Hernia, Fracture, Diffuse Lung Density, Calcified Pleural Plaque, Free Air, Calcified Granuloma, Metastatic Disease, or Pulmonary Nodule

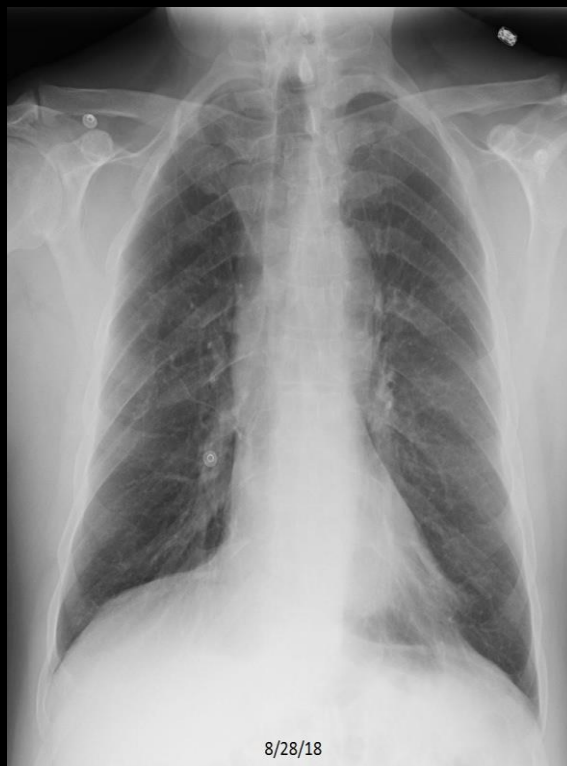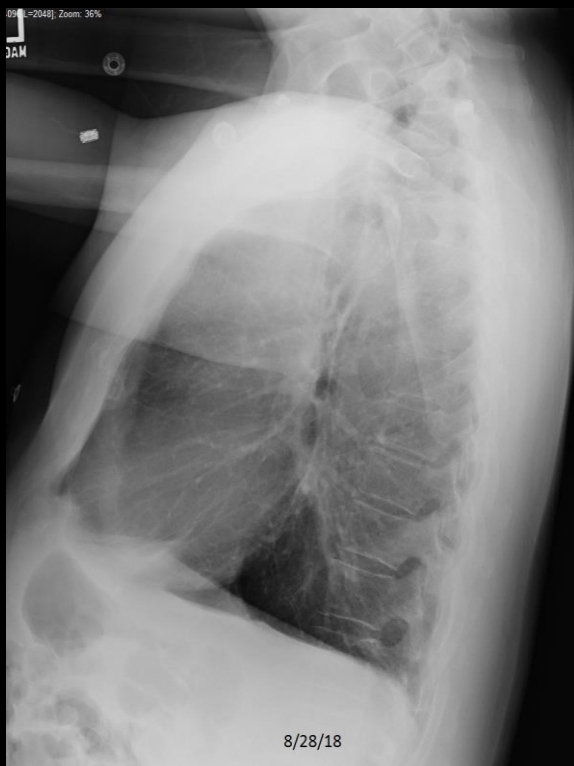


Review Quiz Case 6 of 10  
Cardiomegaly without Failure

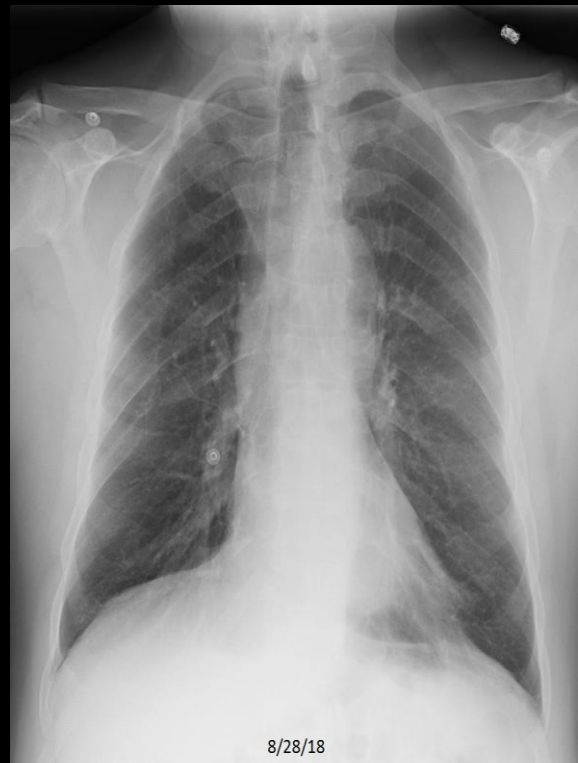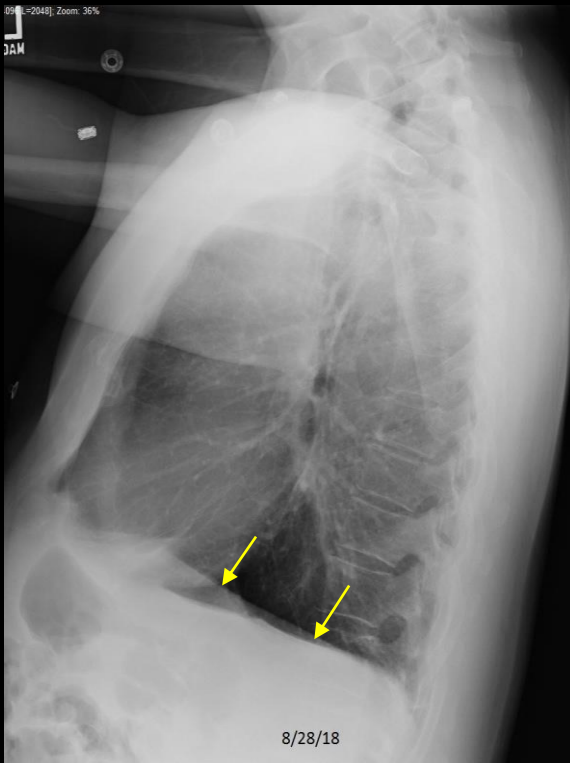


## Review Quiz Case 7 of 10

Normal, CHF, Pneumonia, Emphysema, Cardiomegaly without Failure, Atelectasis/Scar, Focal Chest Density, Pleural Effusion, Hiatal Hernia, Fracture, Diffuse Lung Density, Calcified Pleural Plaque, Free Air, Calcified Granuloma, Metastatic Disease, or Pulmonary Nodule

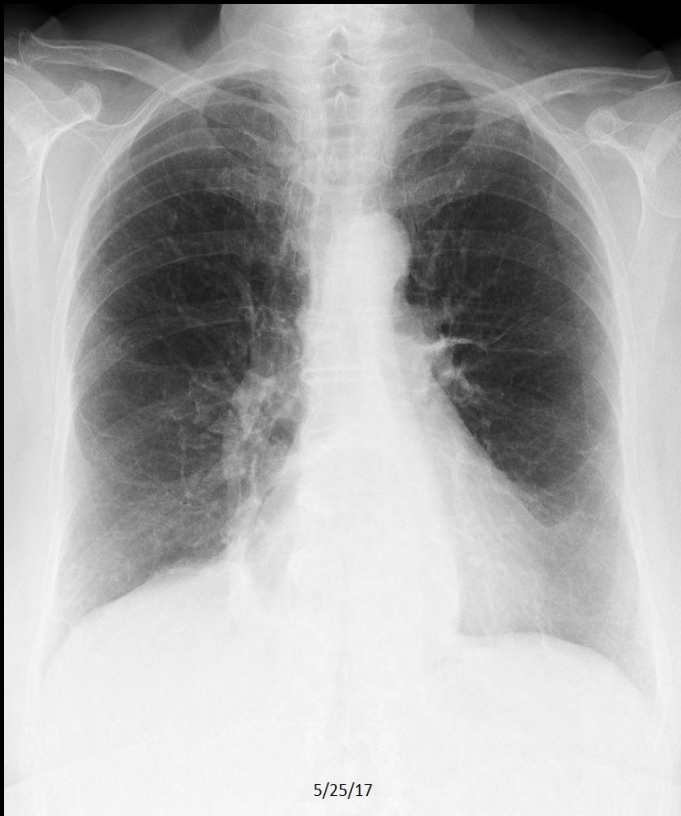
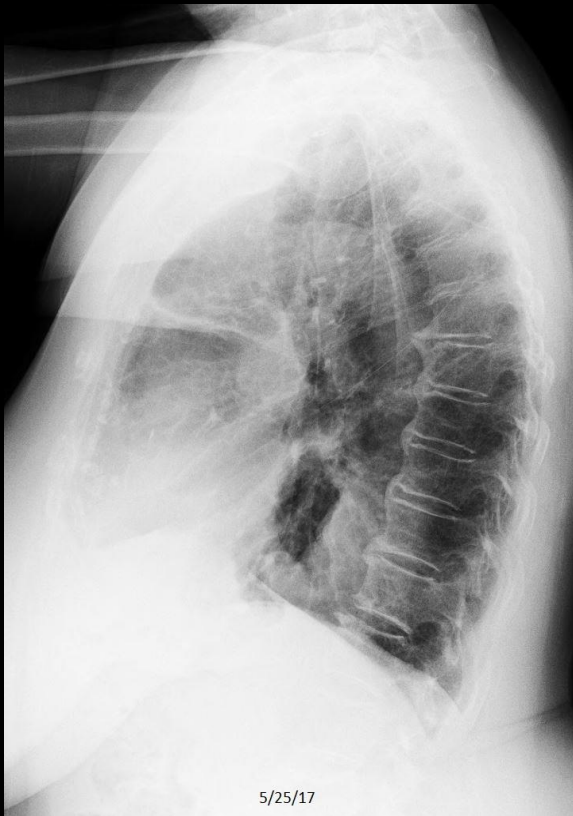

Review Quiz Case 7 of 10  
Emphysema



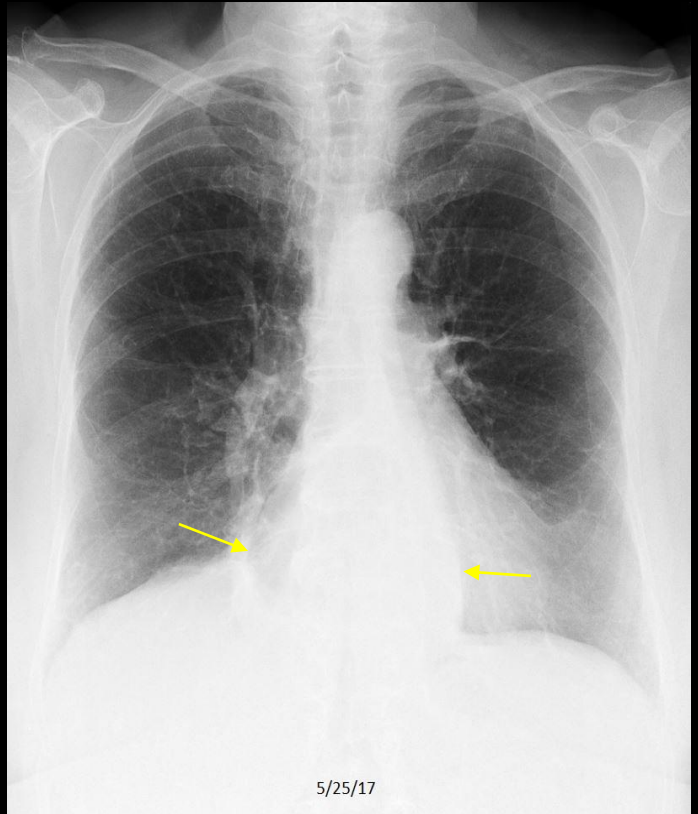
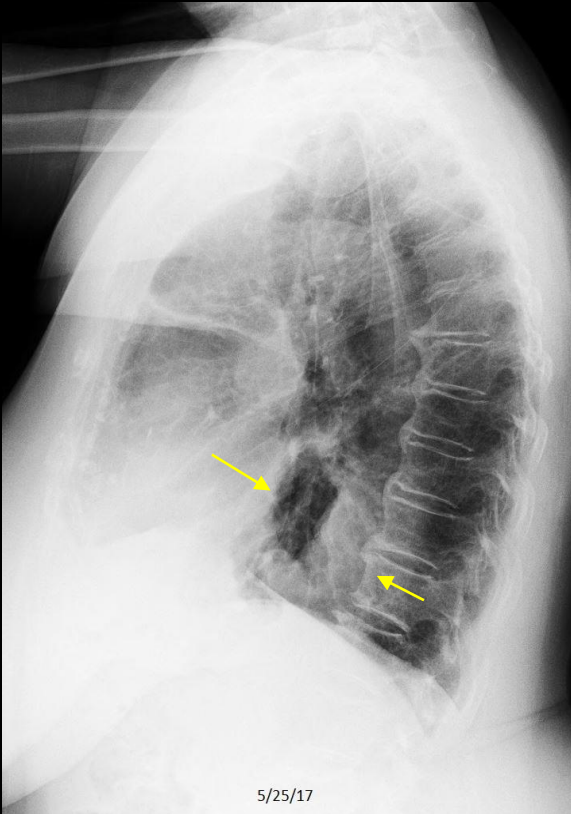
## Review Quiz Case 8 of 10

Normal, CHF, Pneumonia, Emphysema, Cardiomegaly without Failure, Atelectasis/Scar, Focal Chest Density, Pleural Effusion, Hiatal Hernia, Fracture, Diffuse Lung Density, Calcified Pleural Plaque, Free Air, Calcified Granuloma, Metastatic Disease, or Pulmonary Nodule



C456. 92 year old with chest pain following injury sustained in a fall.

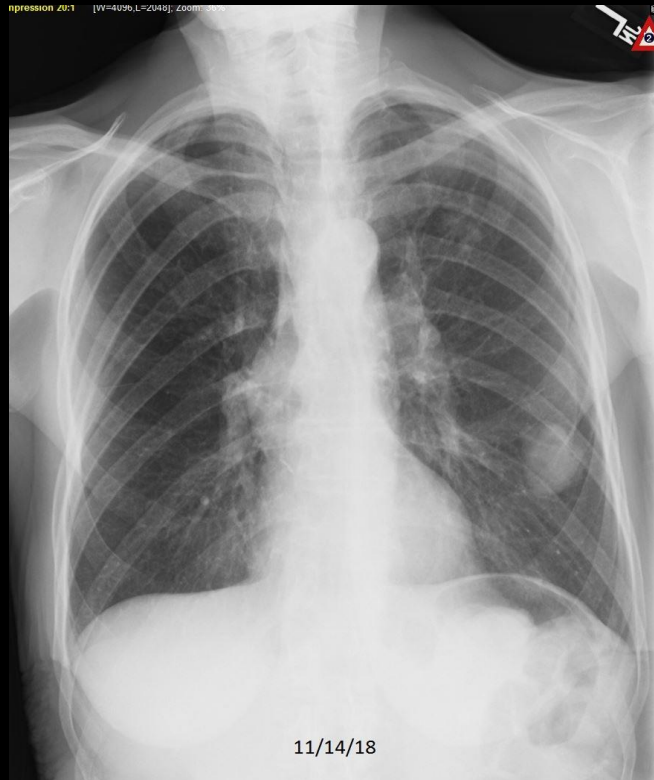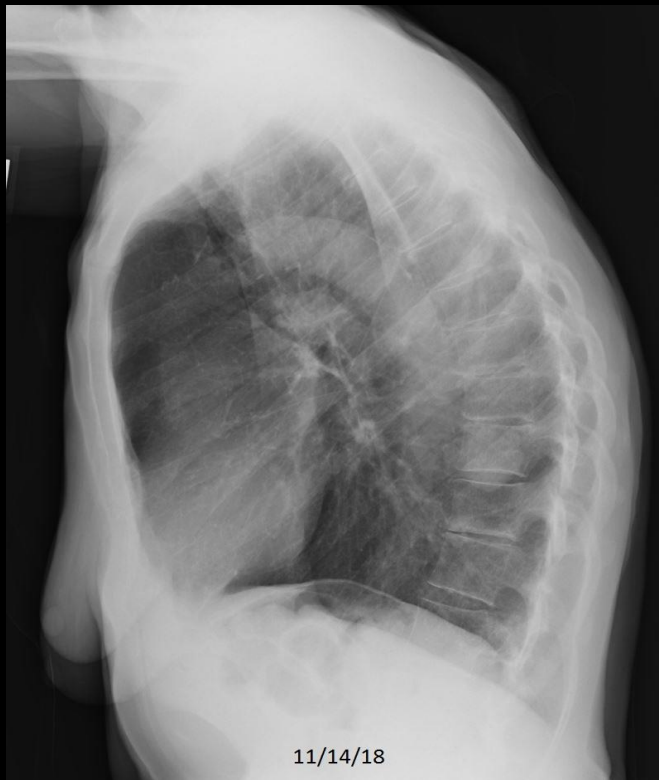Review Quiz Case 8 of 10  
Hiatal Hernia



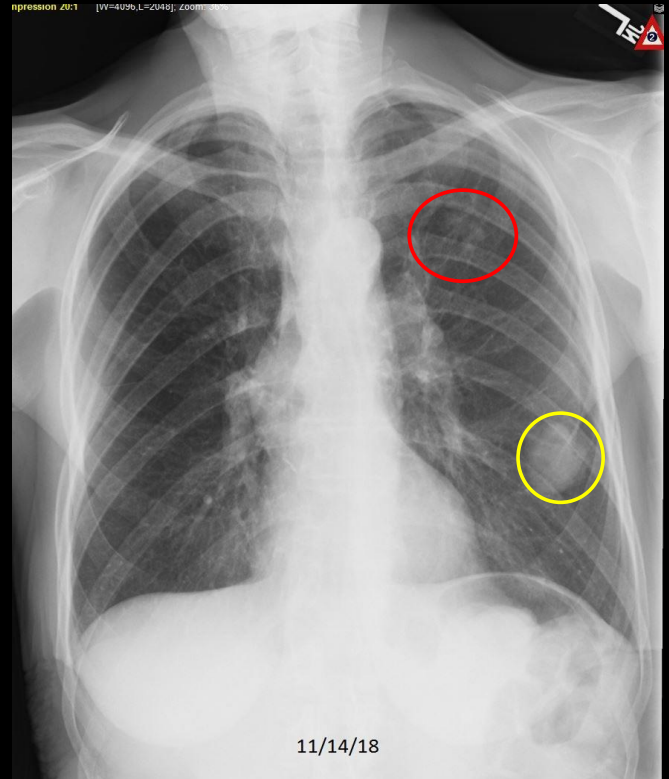
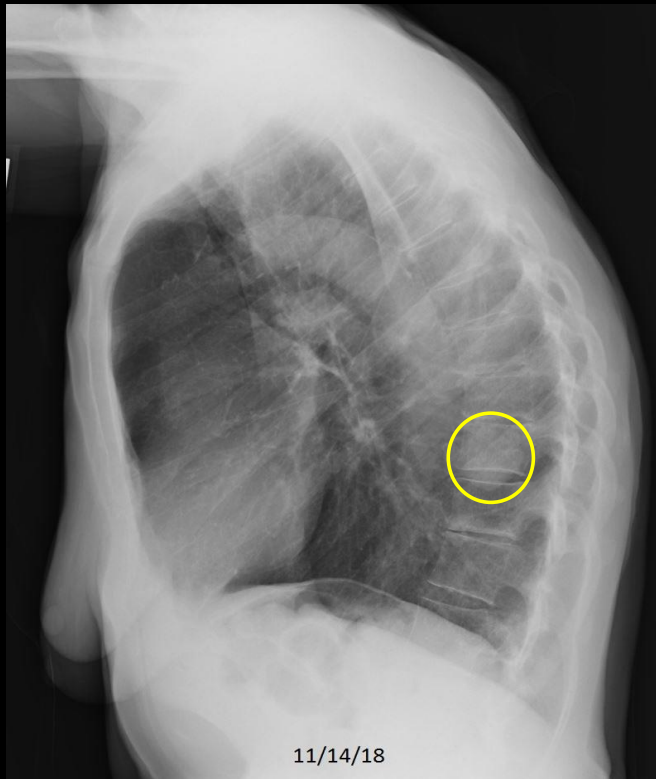
C456. 92 year old with chest pain following injury sustained in a fall. **Hiatal hernia.**

## Review Quiz Case 9 of 10

Normal, CHF, Pneumonia, Emphysema, Cardiomegaly without Failure, Atelectasis/Scar, Focal Chest Density, Pleural Effusion, Hiatal Hernia, Fracture, Diffuse Lung Density, Calcified Pleural Plaque, Free Air, Calcified Granuloma, Metastatic Disease, or Pulmonary Nodule

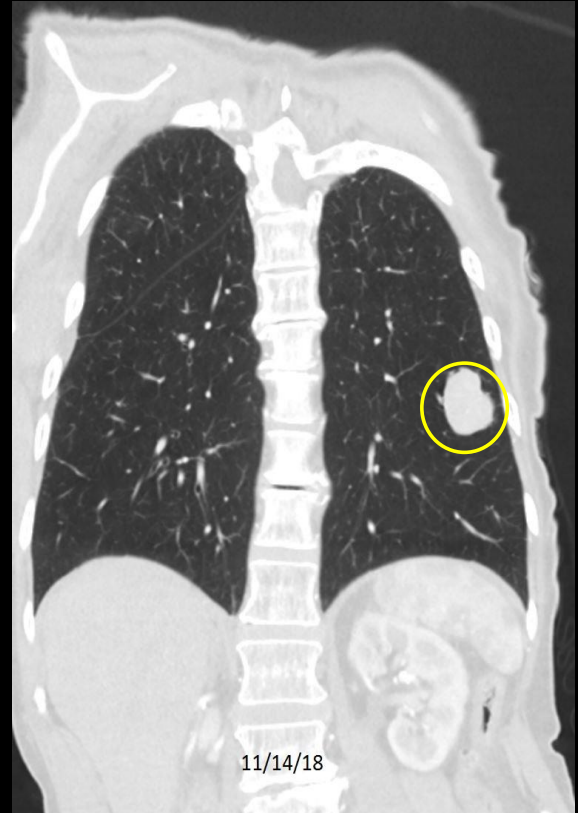
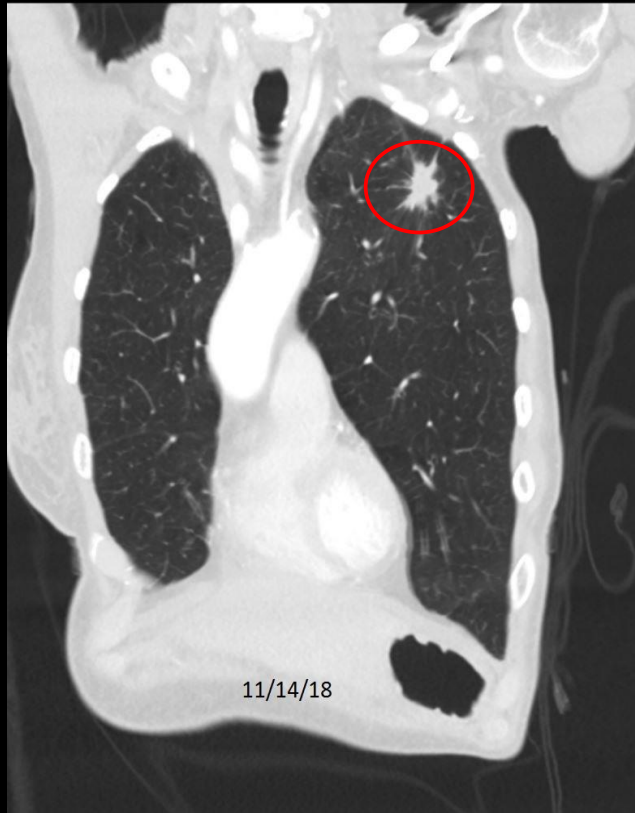

Review Quiz Case 9 of 10  
Focal Chest Density and Pulmonary Nodule



C649. 82 year old woman with cough and dyspnea. Left focal chest density (borderline for nodule/mass). Left upper lobe pulmonary nodule.

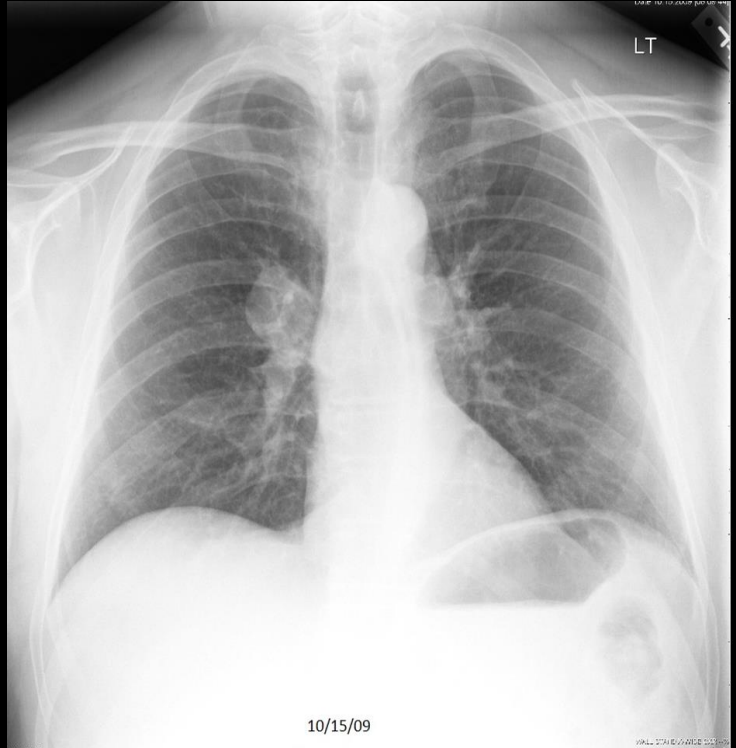
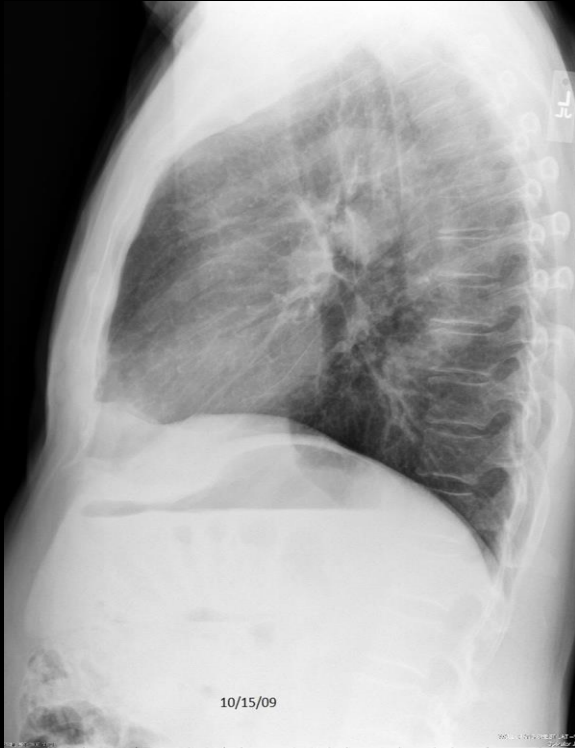Review Quiz Case 9 of 10  
Focal Chest Density and Pulmonary Nodule



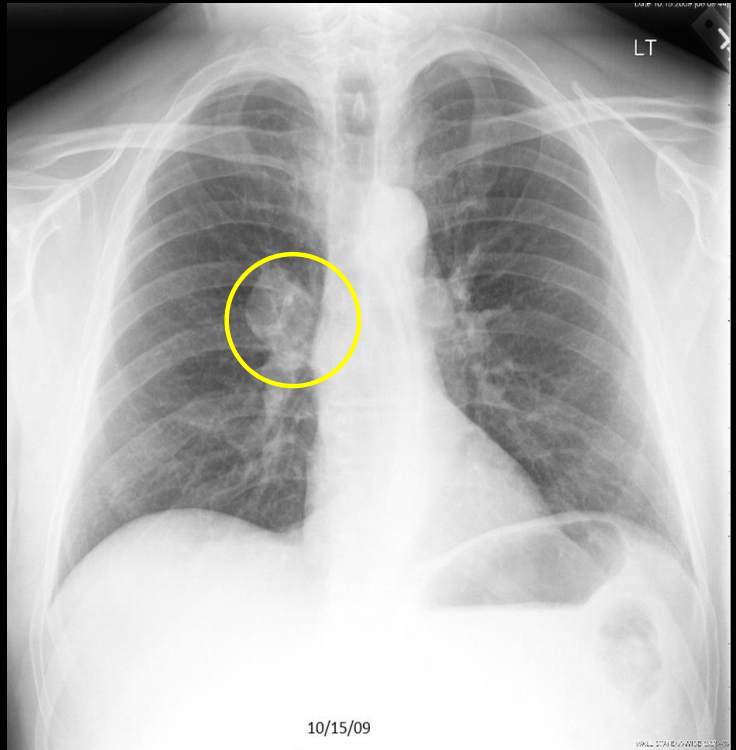
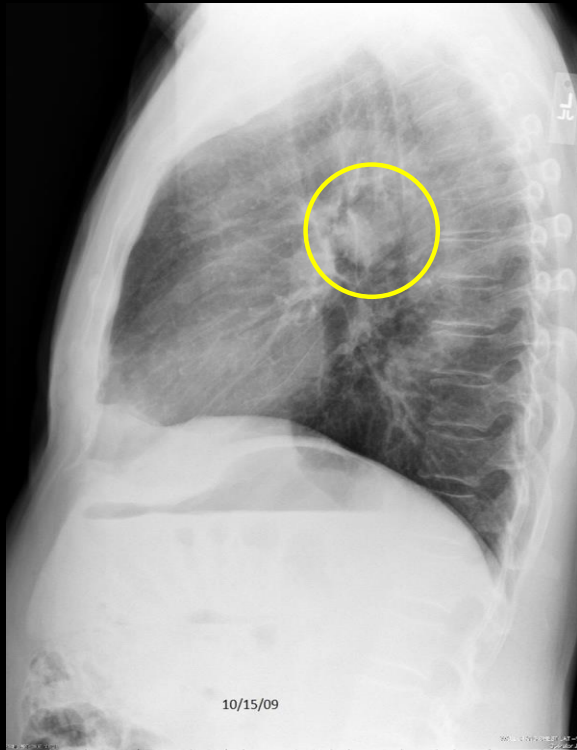
C649. 82 year old woman with cough and dyspnea. . **Left focal chest density** (borderline for nodule/mass). **Left upper lobe pulmonary nodule**. Small cell lung cancer.

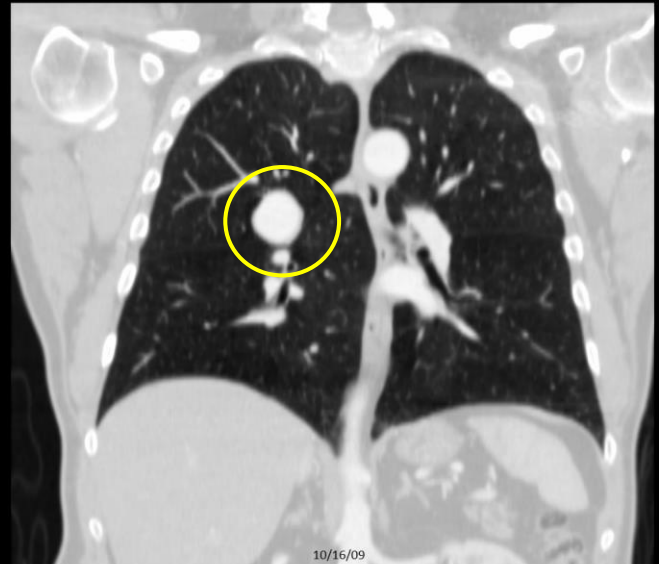
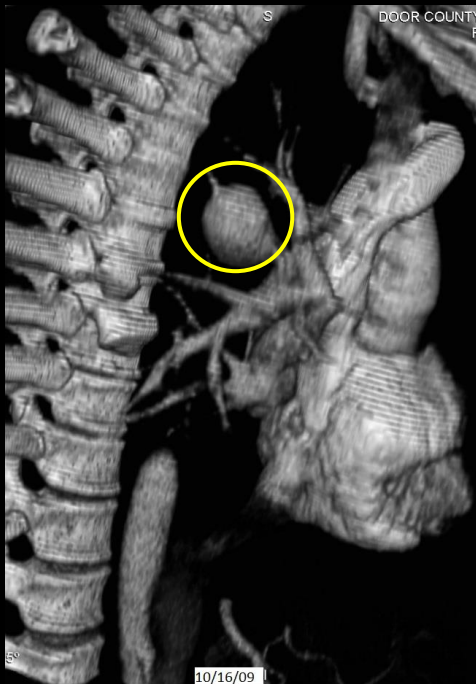
## Review Quiz Case 10 of 10

Normal, CHF, Pneumonia, Emphysema, Cardiomegaly without Failure, Atelectasis/Scar, Focal Chest Density, Pleural Effusion, Hiatal Hernia, Fracture, Diffuse Lung Density, Calcified Pleural Plaque, Free Air, Calcified Granuloma, Metastatic Disease, or Pulmonary Nodule



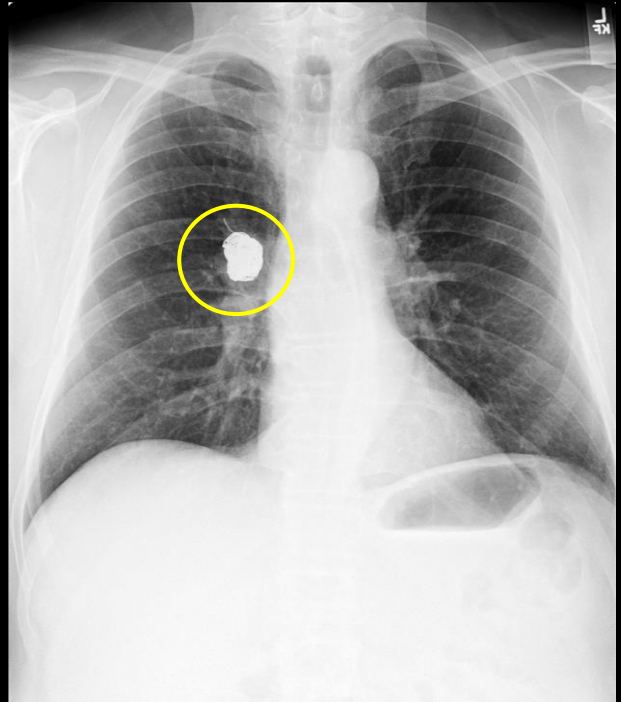
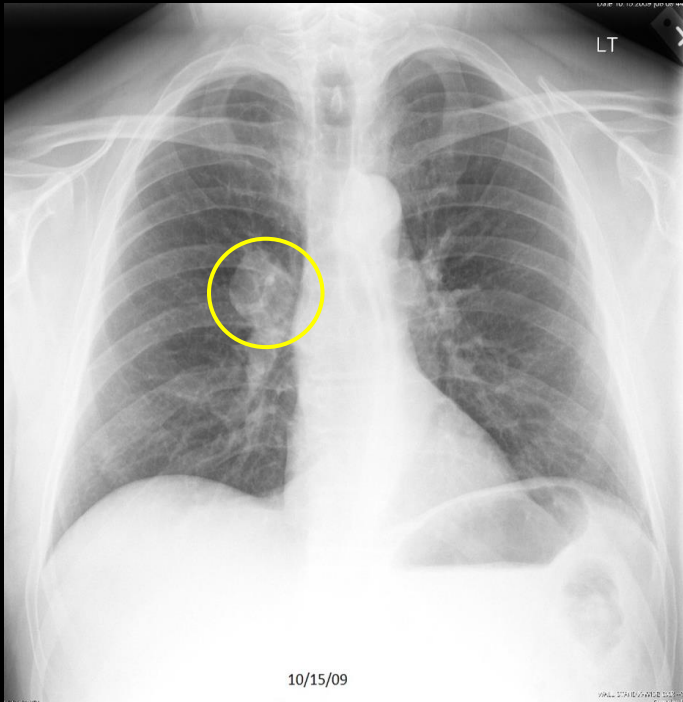
Review Quiz Case 10 of 10  
Focal Chest Density (mass) versus Pulmonary Nodule





C509. 67 year old man with acanthosis migrans. Right pulmonary mass. CT shows vascular malformation.

Review Quiz Case 10 of 10  
Focal Chest Density (mass) versus Pulmonary Nodule



# RECAPTIULATION

## PULMONARY NODULE

**INDICATIONS:** Almost always an asymptomatic incidental finding.

**FINDINGS:** Well defined pulmonary density measuring less than 30 mm. Pulmonary masses (lesions > 30 mm) are generally handled as “focal lung density”. Please see separate presentation.

**IMPRESSION:** Pulmonary nodule. Comparison with prior studies to determine chronicity. Further work-up, typically starting with CT then (depending on results) proceeding to PET.

**COMMENT:** Cases in this category often require further work-up, frequently with additional imaging. However, at the time of the initial CR, the radiologist will not have these additional studies. The radiologist still needs to recognize the finding and that something more needs to be done.

# UpToDate Points

"A pulmonary nodule is defined on imaging as small ( $<30$  mm), well defined lesion completely surrounded by pulmonary parenchyma."

"The initial evaluation should use clinical features, radiographic features, and occasionally quantitative models to determine the likelihood of malignancy. The likelihood of malignancy then determines further management, usually computed tomography (CT) surveillance or biopsy."

"The majority of incidentally nodules are benign."

"An incidental pulmonary nodule is benign if it demonstrates fat (pulmonary hamartoma) or a characteristic calcification pattern (e.g., granuloma, hamartoma) or if it is stable on CT for a defined period of time (i.e.  $> 2$  years for solid and  $> 5$  years for subsolid nodules.)"

Weinberger SE, McDermott S. Diagnostic evaluation of the incidental pulmonary nodule. UpToDate, accessed 3/26/20 (last updated 6/21/19).

Chest Radiography  
End of Lecture 16  
Pulmonary Nodule

Go to Lecture 17  
Elevated Hemidiaphragm